An **Anatomy In Clay®** Workbook

Muscles of the Human Hand


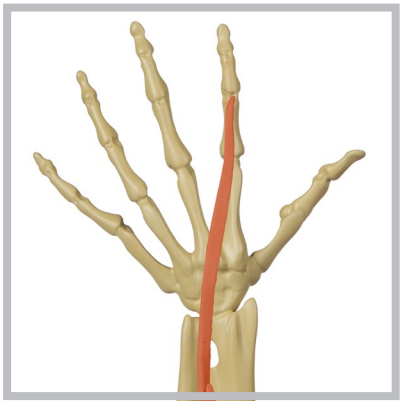
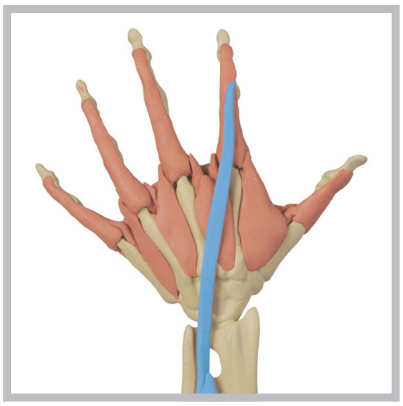


The StepByStep™ Series

by Jon Zahourek

Anatomy In Clay® Publications
A Division of Zahourek Systems, Inc.

Anatomy in Clay® Publications
A Division of Zahourek Systems, Inc.

ZAHOUREK SYSTEMS
zsi@anatomyinclay.com
2198 West 15TH St.
Loveland, CO
80538-3597, USA
[970] 667-9047

A Workbook on

Muscles of the Human Hand

The StepByStep™ Series

Author Jon Zahourek

Jon Zahourek is widely known as the author of an innovative and revolutionary approach to the study of anatomy, which features kinesthetic learning through building clay muscles onto the Maniken® model and a range of other, comparative vertebrate models. His series of CoreData™ intensive workshops are attended by participants from every continent. He has held posts at the University of Denver, Parsons School of Design, Bank Street College, New School of Social Research, Art Students League, and New York Academy of Art. With Columbia University's Department of Rehabilitation Medicine, he was co-investigator of a study in 1982-83 comparing his Anatomy In Clay® System to traditional anatomy study.

Zahourek retired from Zahourek Systems, Inc. in 2009, and now is active as Jon Zahourek, Artist & Anatomist, and as the Chairman of the Board in the not-for-profit Formative Haptics™ Center, which researches the neuroscience of learning through the creative act by forming analyses in the hands.

Author's Notes

This workbook focuses on the human hand, and is a companion to other titles in my Human StepByStep™ series. These workbooks allow learners to discover similar patterns of bone, muscle, nerve, and blood vessels, and to explore the same anatomy in other animals.

Important Note About Terms in This Workbook

The traditional rule for muscle attachment sites holds that when a muscle belly contracts, one of its attachment sites on a bone is called the origin, representing the more stable position. The other site is called the insertion and is more mobile. "Open-chain" limb movements—such as in waving the hand—are situations when the anatomical meaning of these terms holds true. This is because in these cases the hand is more mobile than the forearm, and therefore the muscle attachment sites on the forearm are considered insertions. But the convention does not account for "closed-chain" movements—such as grasping and hanging from a branch. In those cases, the hand is stable but the forearm and body are mobile, reversing the functional meaning of the terms. Nearly every muscle has the potential to be either stable or mobile at different times.

Consequently, if insertion and origin sites are considered to be fixed concepts, therefore inconsistent—and incorrect—meanings for the terms arise. In this workbook, I choose to use a different, consistent application for the attachment terms to avoid this problem: Each muscle is described as having a proximal attachment (indicated in red) and a distal attachment (indicated in blue). Note that because the scale model of the hand used in this workbook does not include a complete forearm, many of the proximal attachment sites cannot be illustrated, so that only the distal attachments, in blue, are shown.

Because ligaments, unlike muscles, do not contract, their attachments are always stable relative to one another. Therefore, they are always represented only in blue.

Workbook Procedures

This *StepByStep Workbook* covers only the muscles and tendons of the hand and wrist using the hand and distal wrist models of the Anatomy in Clay® SuperManiken™ series (75% of life-size) of models, though the MidiManiken™ series (60% of life-size) of models works just as well. In this workbook, each muscle is the focus of a two-page spread appropriate to the muscle that is the subject.

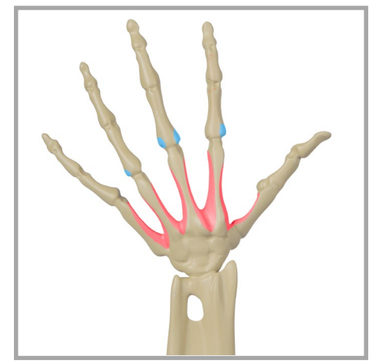

13

Shows the attachment sites for the muscle with the proximal site in red and the distal in blue.

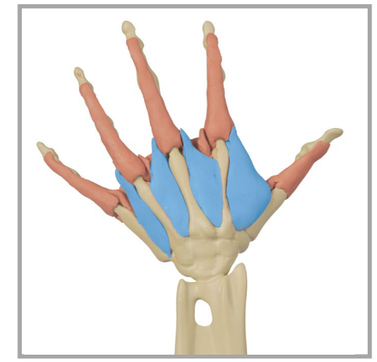

15

Shows in blue the muscle in place in the context of the muscles built so far.

dorsal interossei mm.

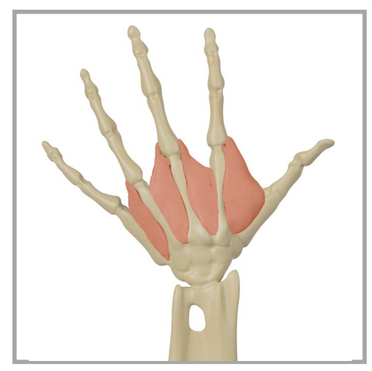

14

Shows the muscle in isolation as it connects to the sites on the model.

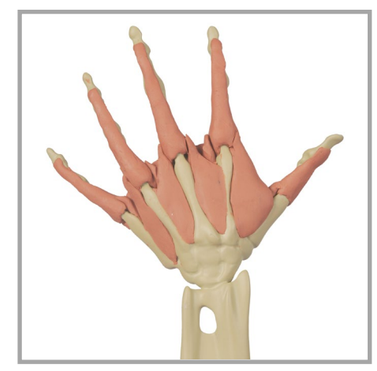

16

Shows the muscle in place as it should appear in an actual building session.

dorsal interossei mm.

The first occurrance of any formal term is noted in the Table of Contents, pages 86–87. The type of structure may be abbreviated following standard anatomical style, as listed below.

l. ligament	*ll.* ligaments (plural
m. muscle	*mm.* muscles (plural)
t. tendon	*tt.* tendons (plural)

transverse metacarpal l.

1

In this first step, we encounter a variation of the rule about origins and insertions discussed in Author's Notes.

In the case of this ligament, all the attachment sites are blue because they are not muscles. Each site is stable relative to the other at all times.

Here you see that this ligament attaches to a ray of metacarpal proximal to its condyle. Crossing over the condyle it fastens to the base of its proximal phanlanx. Each pair of sites is linked to the other rays by a band of ligament.

2

All of the ligaments and muscles in this workbook are built with terra cotta-colored clay. In this step, the transverse metacarpal ligament is shown as a buff-colored strap to emphasize that it is not muscle.

Make a band of clay just under 1/8-inch thick. Attach it to the edges of the palmar bases of the proximal phalanges of digits 2-5. This structure is ligament as well as somewhat flexible fibrocartilage.

Make four grooves in the band. This will help redirect the tendons as they travel through the wrist and fan out, coming into alignment along the length of the fingers

transverse metacarpal l.

3

Attached to the heads of the metacarpals and the phalanges, this ligament holds the metacarpal bones in a hand shape. The thumb is not included and therefore is free to move independently.

.

4

dorsal digital hoods

5

The dorsal digital hoods attach to the dorsal surfaces of each phalanx of all three of the phalanges of each digit, unifying them.

6

Flatten tubes of clay that are 1/4-inch by 3-inches to about a thickness of 1/16-inch and lay them over the dorsal fingers and thumb.

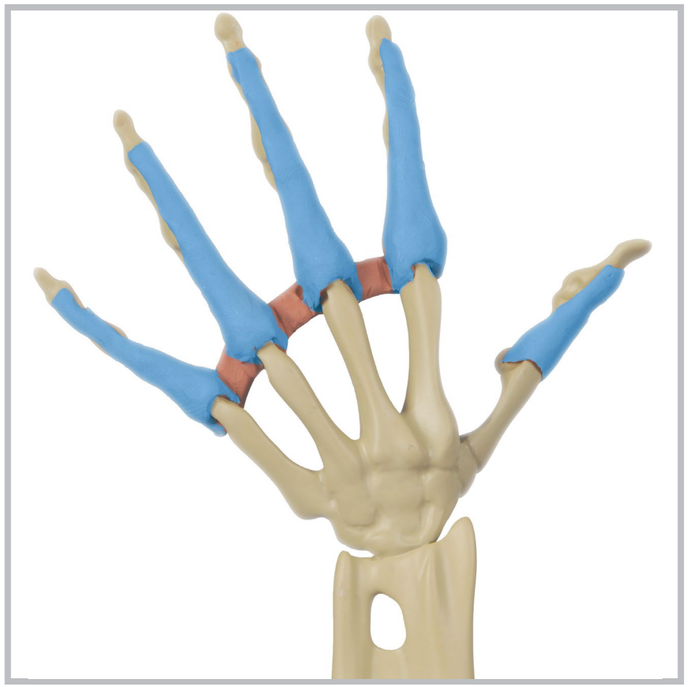

dorsal digital hoods

7

At the proximal ends of the proximal digits, the hoods wrap around the metacarpal heads, fastening to the transverse metacarpal ligaments and to their joint capsules.

8

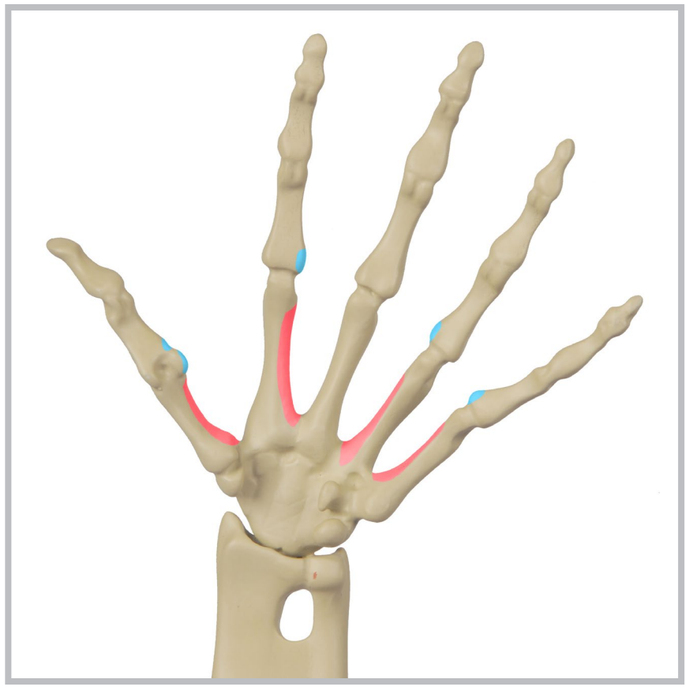

9

"Ray" indicates a metacarpal bone and its finger. Beginning with the thumb, the rays of the hand are called I, II, III, IV, and V.

Ray number III lacks an attachment site for this muscle. All the other metacarpals provide sites that are along along the edges that are nearest the main ray.

Each tendon of these four muscles crosses the metacarpo-phalangeal joint and attaches to a tubercle on the base of its proximal phalanx.

palmar interossei mm.

10

Taper the ends of four 1/4-inch tubes of clay. Fit one end of each into the notch between the metacarpal bases and the other end to the proximal phalanges.

Note that on the medial metacarpal of digit I (the thumb), the tendon partly encapsulates the sesamoid bone at the base of its proximal digit.

11

The tendons of these muscles cross the metacarpo-phalangeal joints on the dorsal sides of the *transverse metacarpal* ligament.

When activated, these medial and lateral pairs of muscles fan the fingers from side to side on their metacarpal heads. The fingers in this model are all abducted *away* from the main ray.

palmar interossei mm.

12

The tendons of all these muscles also spiral around the proximal phalanx and onto the dorsal hoods of all the digits.

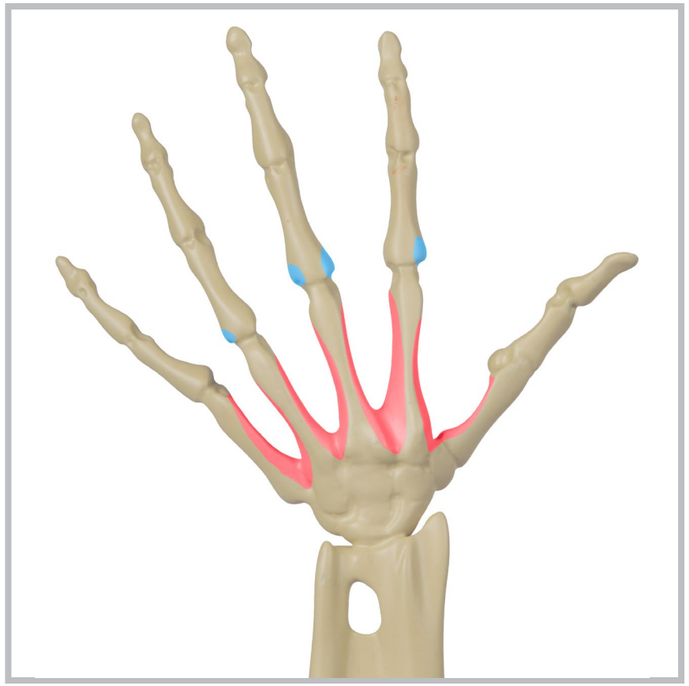

13

These muscles are on the dorsal side, commonly called the "back" of the hand. Only the main ray (digit III) has attachment sites on both sides.

dorsal interossei mm.

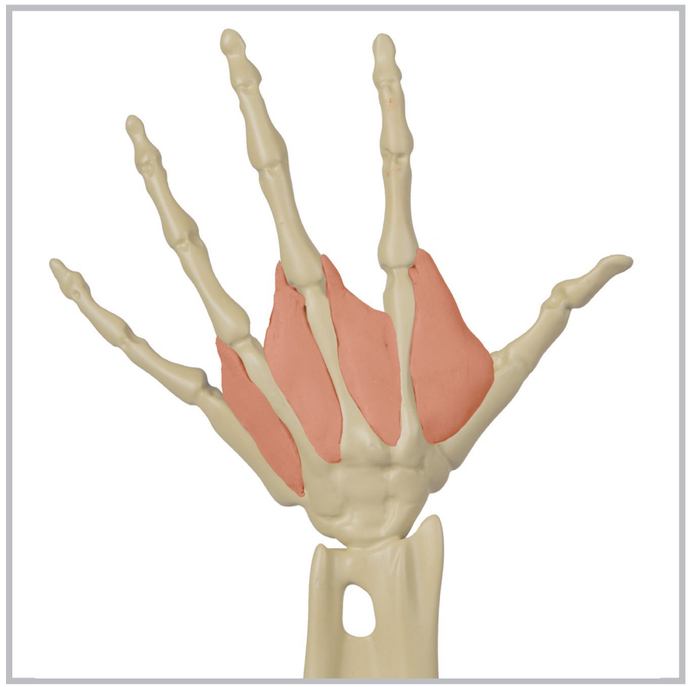

14

A series of four fan-shaped muscles fit into the "V" spaces between the metacarpal bones. Each of these fairly thick sheets of muscle tapers to a tendon that crosses the metacarpophalangeal joint, attaching to the digital bases opposite those of the *palmar interossei mm*.

This series is considered to be *ab*ductors of the three central fingers, though, unconstrained by the transverse metacarpal ligament, the thumb can be dorsally *ad*ducted to lie along the index finger as well.

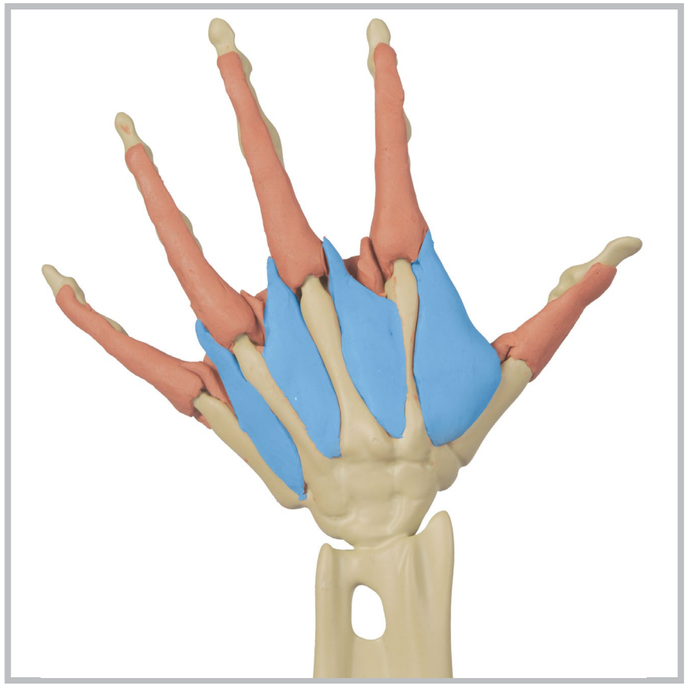

15

See how the tendons of these muscles cross the metacarpophalangeal joints on the dorsal side of the *transverse metacarpal* I.

dorsal interossei mm.

16

The diagonal tendons from between the ring and middle fingers and that from between the index and middle fingers abduct in the opposite direction. They both abduct the main ray away from *its own* central axis, "waggling" the middle finger from side to side in abduction and adduction.

Note that there are not yet shown any abductors of the little finger (*digiti minimi*) nor of the thumb. Those two muscles are among the last muscles that we will build.

flexor carpi radialis m. (distal attachments)

17

In our bodies, a single flexor tendon forks into two attachment sites in our palm. These sites are on the bases of the II and III metacarpal bones.

This single tendon joins into a muscle belly whose proximal tendon attaches further up the arm near the elbow (not shown in this workbook).

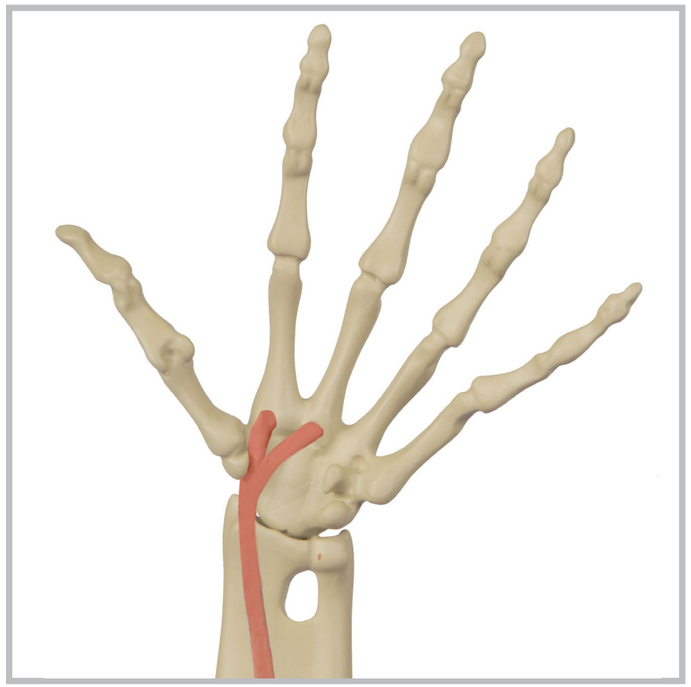

18

The fork in this tendon occupies a site in the deepest level in the palmar hand. At the mid-carpal point, the two tines of the fork merge into a single strong tendon.

From this deepest layer of anatomy in the palm—overlaid by others as yet unbuilt tendons—this muscle belly of this tendon will become the most superficial layer of the forearm.

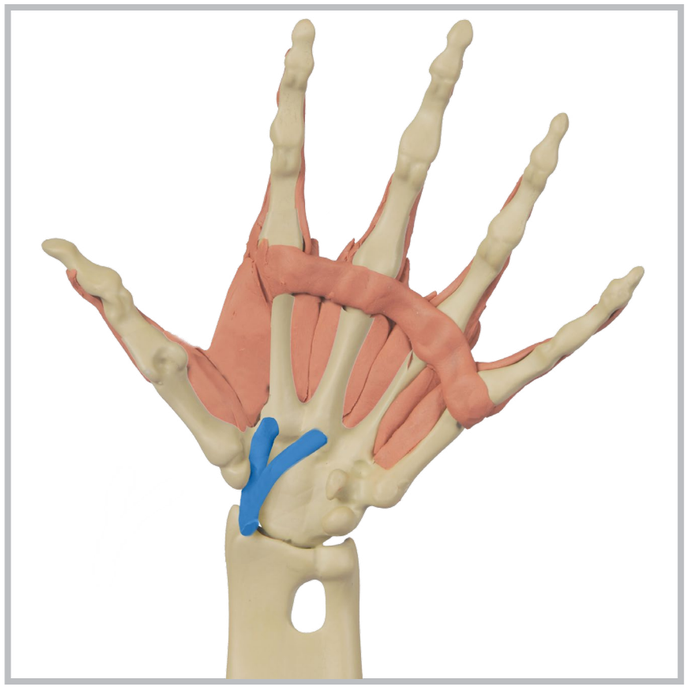

flexor carpi radialis m. (distal attachments)

19

For our purposes in building, we will cut the tendon at the radiocarpal margin. At step number 93, we will complete the tendon.

Here is the stump of the tendon in its context, along with the other muscles we have built so far.

20

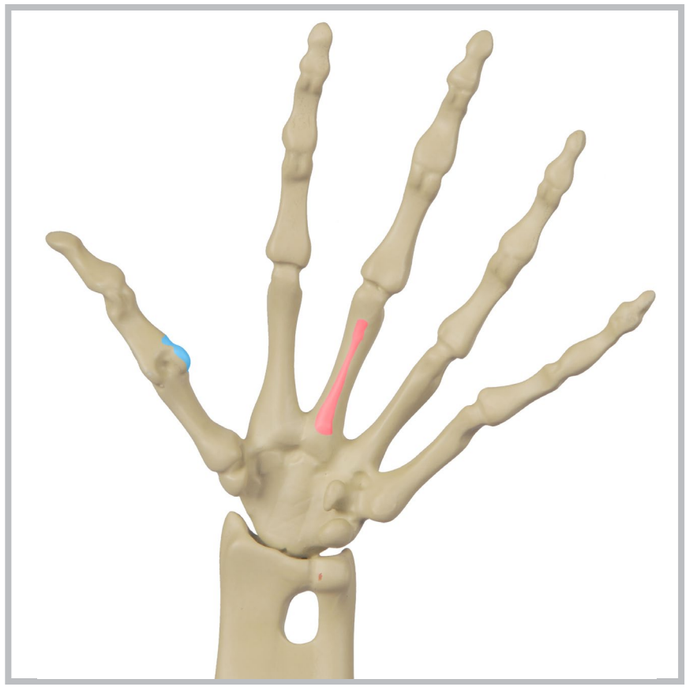

21

The proximal attachment of this adductor muscle of the thumb is on the palmar ridge of the metacarpal of the main ray.

Its distal attachment is to the medial base of the thumb (the pollux) along with the small sesamoid bone that is embedded in its tendon. This sesamoid always follows along with the base of the proximal phalanx of the pollux in its movement.

adductor pollicis transversus m.

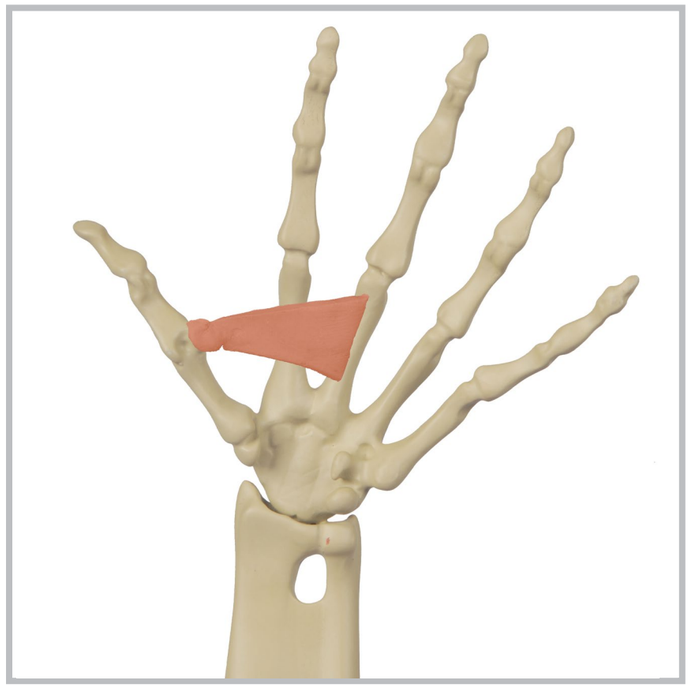

22

In this 1/8-inch thick fan of muscle, it's easy to see the power involved in directly adducting the thumb toward the main ray.

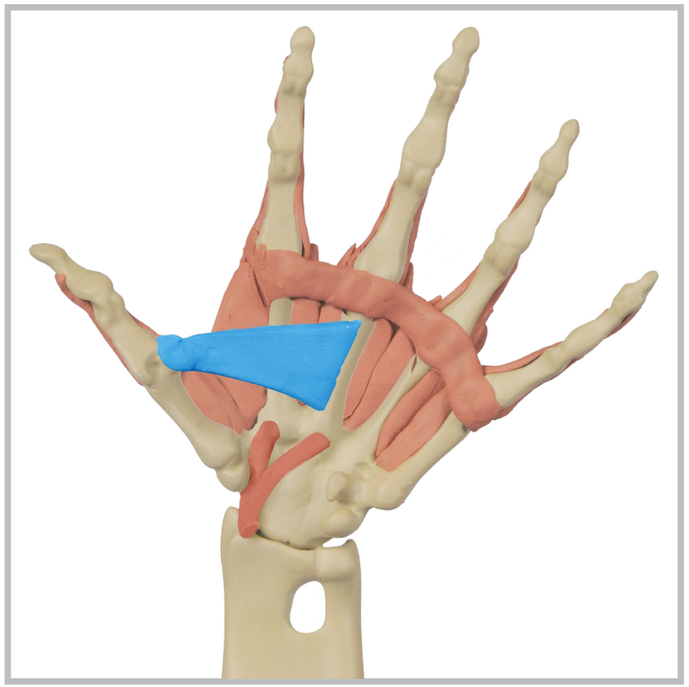

23

This muscle adducts the proximal phalanx of the thumb along with its attendant sesamoid. Recruiting both the dorsal and ventral muscles together produces a very powerful grip—a characteristic common among primates.

adductor pollicis transversus m.

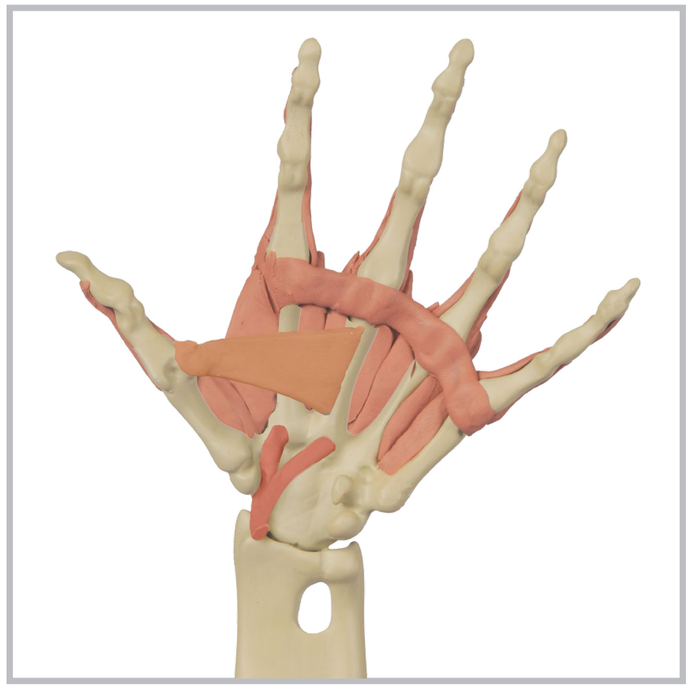

24

Because of the unique "double-saddle joint" at the thumb's base with the trapezium carpal bone, this muscle can swing the thumb through an arc *into* the palm. If there were no palmar fat, fascia, and skin in the way, this motion could bring both attachment sites of the muscle into contact with each other.

25

The final adductor of the thumb is the second, *oblique* head of the *adductor pollicis* m.

One of the attachment sites is on the palmar ridge of the metacarpal that we just built in the *transverse* head of this muscle. This muscle converges to attach to a common tendon with the *adductor transversus* m. and it continues into the proximal carpals.

adductor pollicis obliquus m.

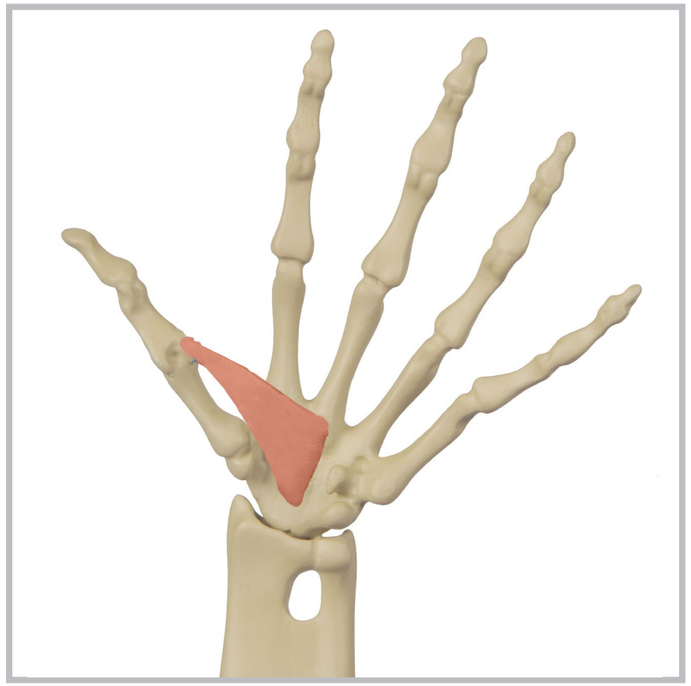

26

This fan of muscle is 1/8-inch thick.

27

This second fan of muscle shares the tip of a "V", which runs from the middle of the hand to the sesamoid and proximal digit of the thumb.

adductor pollicis obliquus m.

28

The gap between the transverse head of this muscle and its oblique head provides a space for the *radial* artery to pass from the dorsal or back of the hand into the ventral or palmar hand.

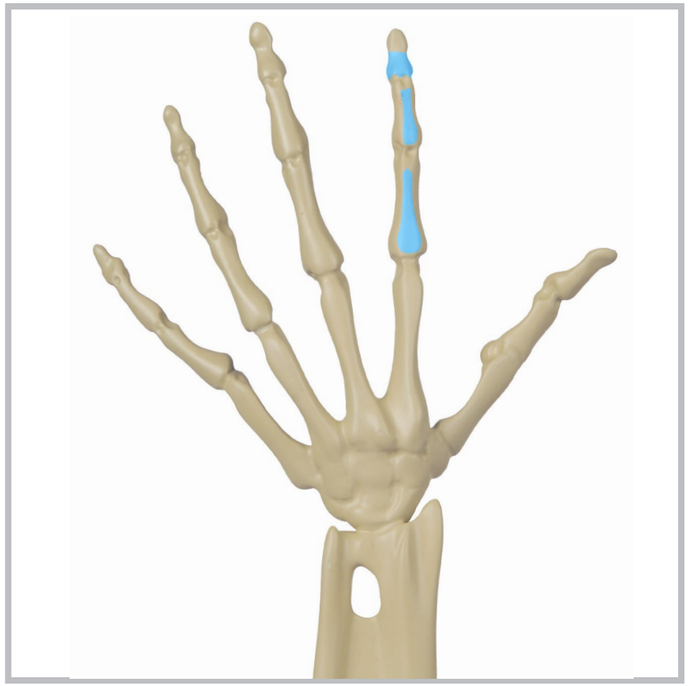

extensor indicis m.

29

Extensor indicis m. attaches on the dorsal surface—or dorsum—of the 1st phalanx of the index finger. Already covered with the dorsal hood built in a previous step, the tendon of this muscle, continues on through that hood to effect each phalanx of the index finger. The other attachment sites runs from the interosseus membrane in the gap between the distal radius and the ulnar head (not shown in this workbook).

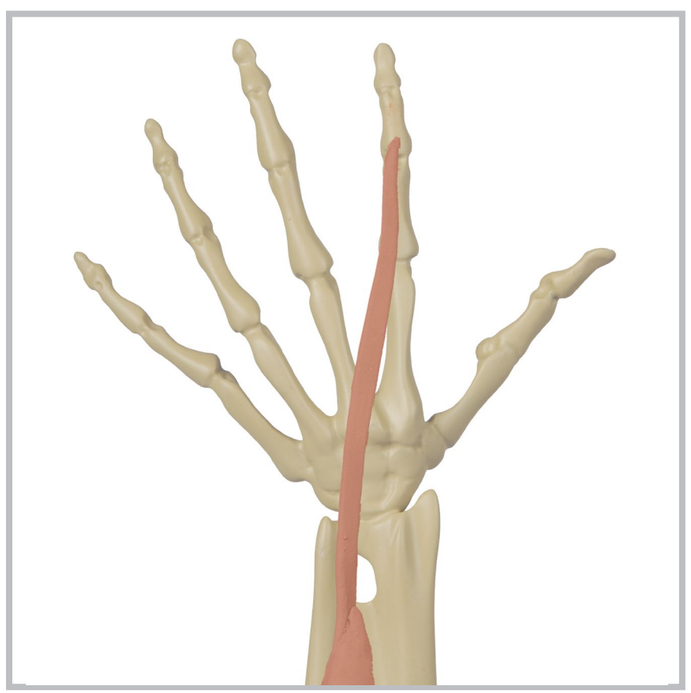

30

Roll out a 1/8-inch tube and flatten it to form this tendon. It has to cross the dorsal hand diagonally to reach the index finger.

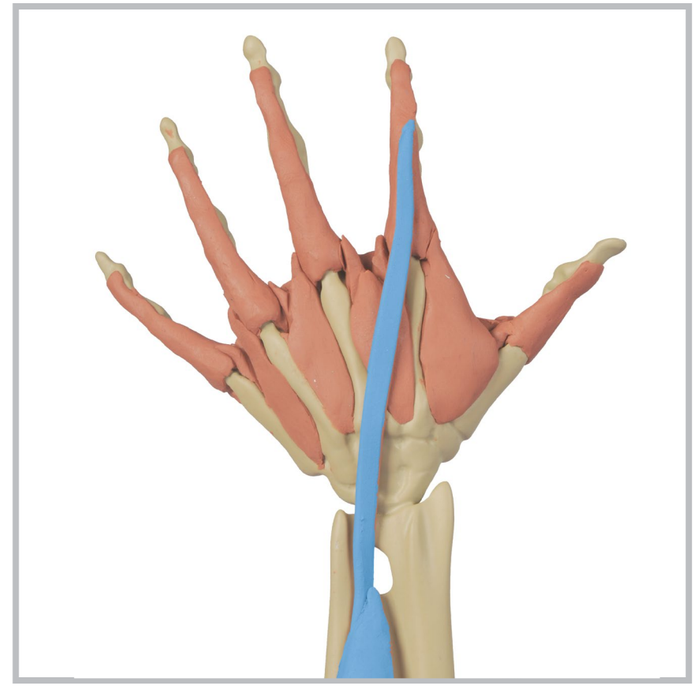

extensor indicis m.

31

At the base of the finger, *extensor indicis* m. is attached to the dorsal hood, aligning it along the length of the index finger.

Notice that the muscle belly and its tendon lies on the *interosseus membrane* that joins the radius to the ulna.

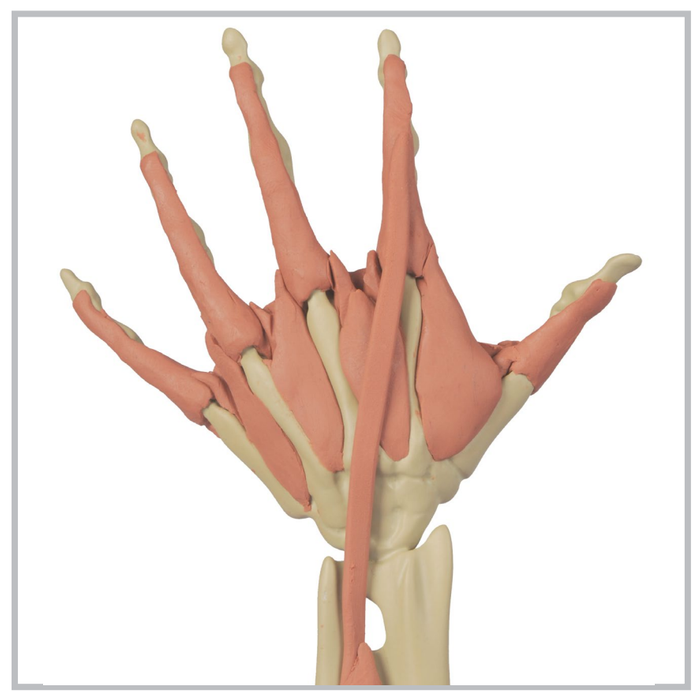

32

33

Two muscles are presented here. These are essentially a long and a short version of the same muscle and they both attach in the hand at nearly the same place, on tubercles at the dorsal bases of metacarpals II and III. *Flexor carpi radialis* m. attaches to the same bones, but on the palmar side.

The other attachment site is far up on the radius at the medial humeral condyle (not shown in this workbook).

extensors carpi radialis brevis & longus mm.

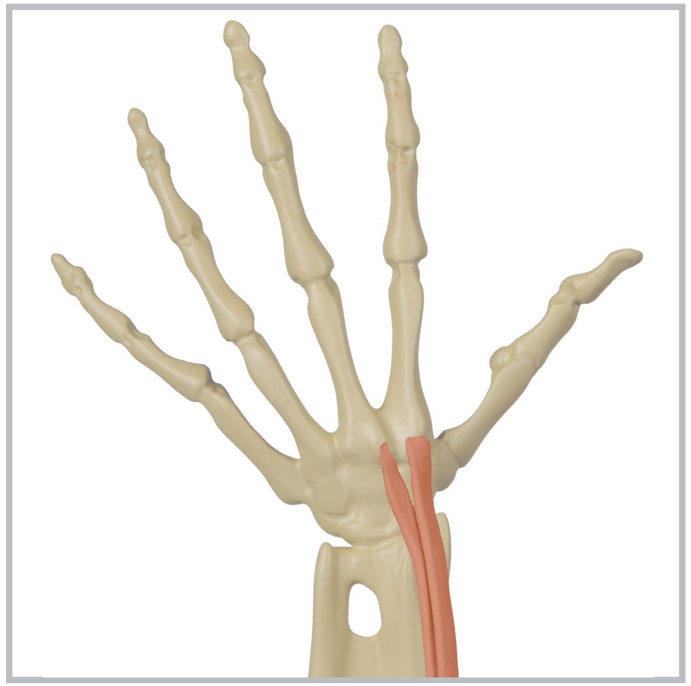

34

These two long tendons—flattened 1/4-inch straps of clay— run next to and parallel each other along the whole length of the radius from the medial humeral condyle (not shown in this workbook) to the hand.

These tendons run distally down the radius and occupy a groove in the distal radius. An eminence on the dorsal radius near the wrist is called the *radial tuberosity*. This bump divides the radius into two channels, a medial groove and a lateral groove. Sulcus is anatomical nomenclature for groove.

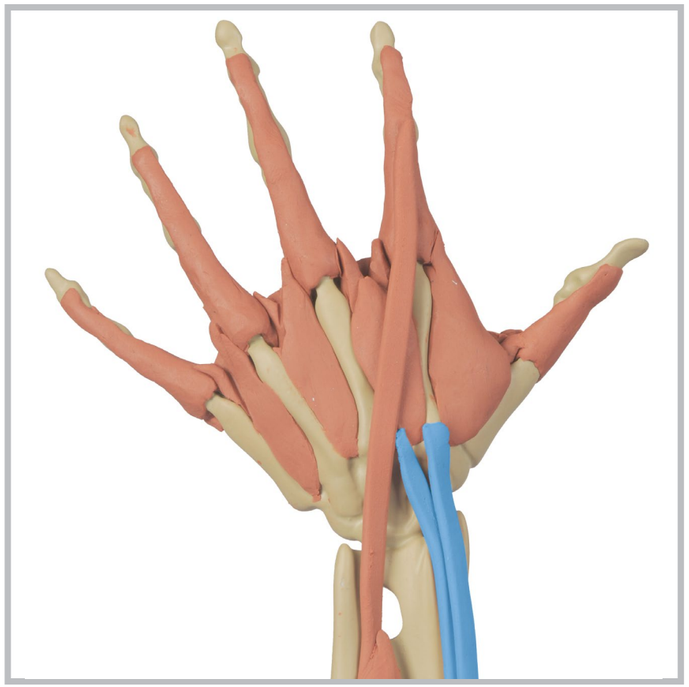

35

Notice how this tuberosity functions as a pulley for the tendons. It changes the direction of the pull of the tendons to go around it rather than directly to the humerus when the wrist is pivoted toward the ulna in *ulnar deviation*.

The *brevis* part of the name alerts you that there must also then be a *longus* muscle. *Radialis*, for example, suggests that there must also be an *extensor carpi ulnaris* m. as well. The term *flexor carpi radialis* m. reminds you that there is also an *extensor carpi radialis m*.

extensors carpi radialis brevis & longus mm.

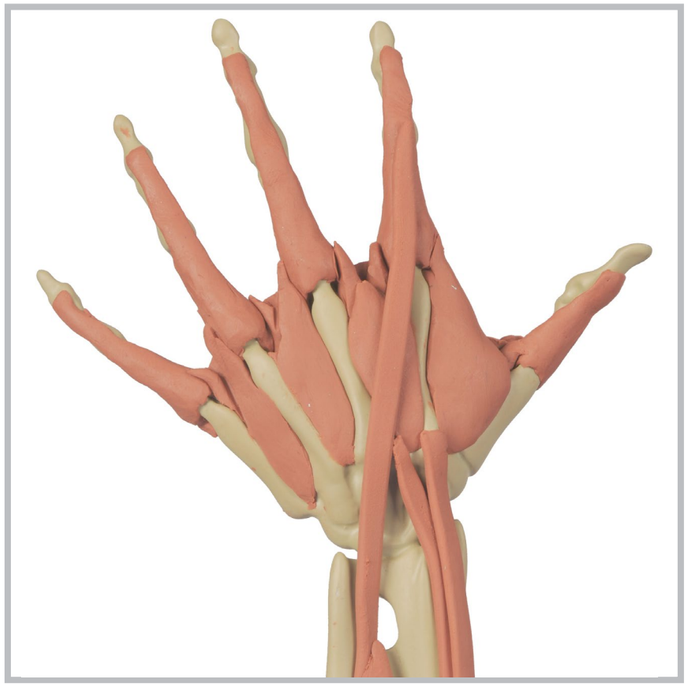

36

Most of the wrist and finger muscles arise from attachments far up the arm—as far as the medial and lateral epicondyles of the humerus (not shown in this workbook). It's useful to think of these long tendons—moved by small muscle bellies—as puppet strings, with the muscles at the elbow acting as if they are the fingers of a puppeteer.

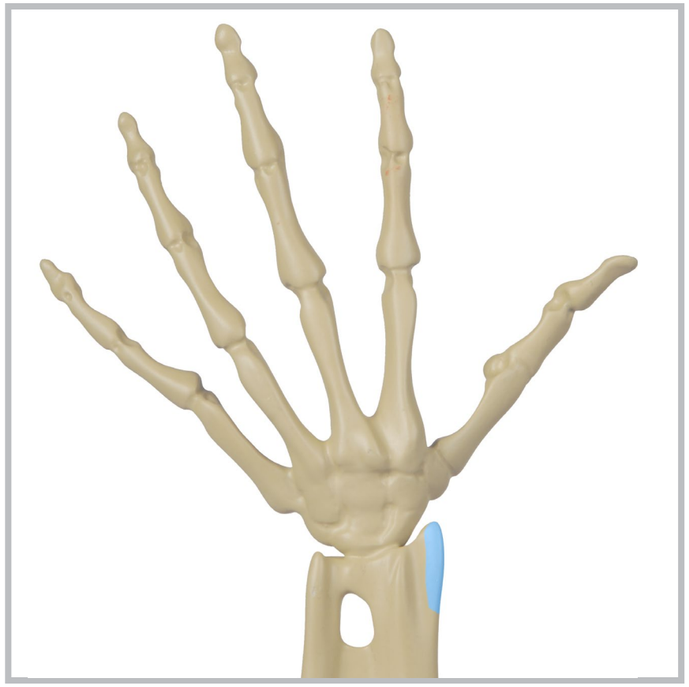

brachioradialis m.

37

The longest muscle in the pectoral subsystem, the *brachioradialis* m. arises from the lateral supracondylar ridge, which is one-third of the way up the humerus (attachment site not shown in this workbook). Although it only crosses the elbow joint, its tendon runs all the way to the tip of the radius, a site known as the radial styloid process.

38

Form this tendon in clay, rolled to a diameter of about 3/16-inch and flattened. It should cover most of the styloid process.

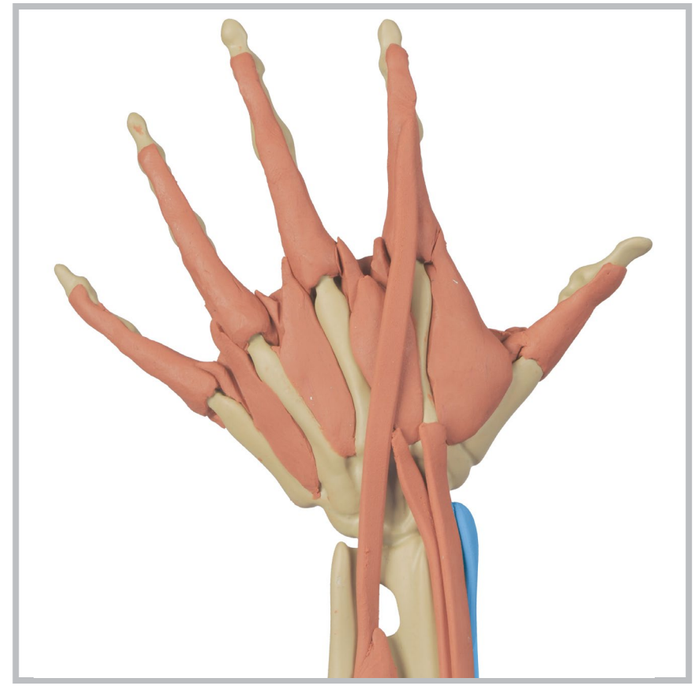

brachioradialis m.

39

The styloid process leads into a ridge on the lateral side of the radius. The formation of this process, along with the ridge of the radial tuberosity, creates the valley-like sulcus through which runs the *extensors carpi radialis* mm.

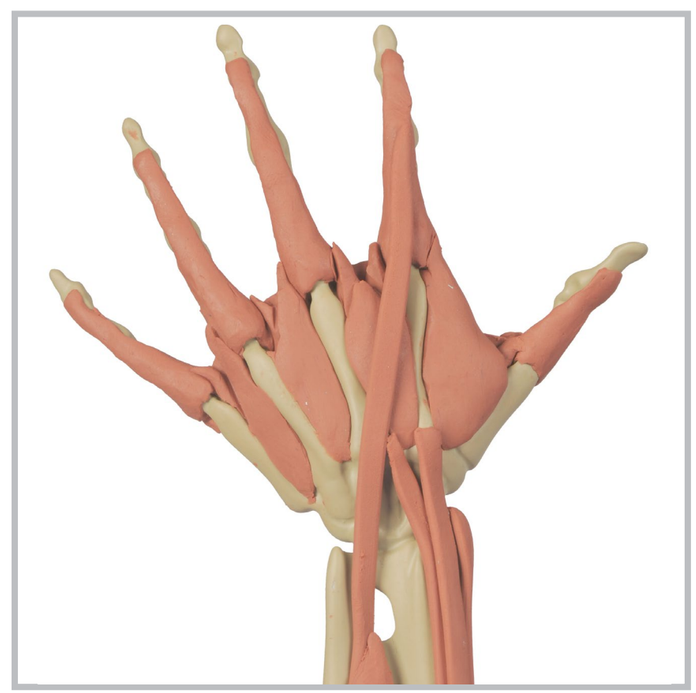

40

extensor pollicis brevis m.

41

This muscle connects the dorsal radius—and the interosseus membrane that joins it to the ulna—to the dorsal surface of the proximal phalanx of the thumb. (The attachment site on the dorsal radius is not shown in this workbook.)

42

Also rolled to about 3/16-inch and flattened, this clay tendon spirals around the ridge of the styloid process and is retained there by a band of connective tissue. This band functions to help redirect the direction of the tendon's pull.

extensor pollicis brevis m.

43

Notice that this muscle and tendon wrap over the tendons of the *extensor carpi* and *brachioradialis* mm. and help hold them in place.

44

45

The *longus* version of the preceding muscle passes over it and onto the distal phalanx of the thumb. The other attachment site just overlaps the brevis version of this muscle, the dorsal ulna, radius, and interosseus membrane (not shown in this workbook). Note that the pollux has only two phalanges, unlike the fingers, which have three.

extensor pollicis longus m.

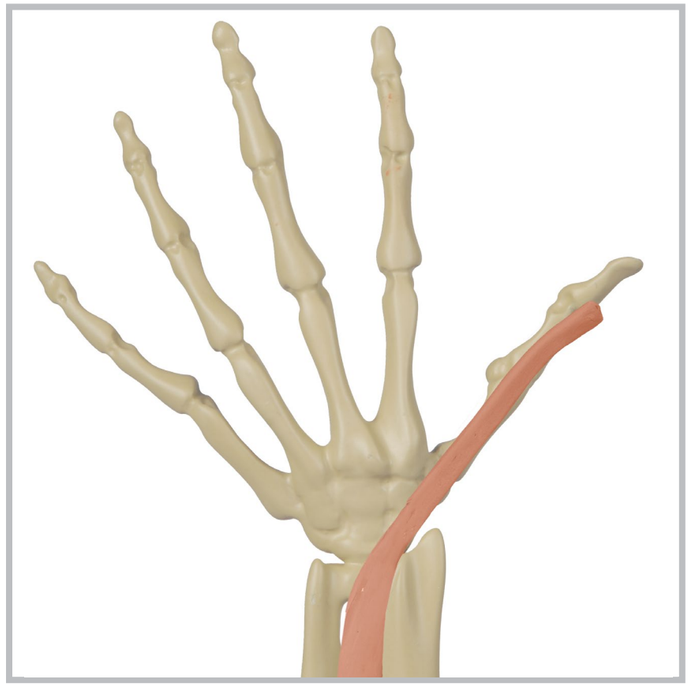

46

Layer another flattened strap of clay to make this muscle. Its tendon runs down and along the channel on the ulnar side of the radial tuberosity instead of wrapping over and around the radial styloid process.

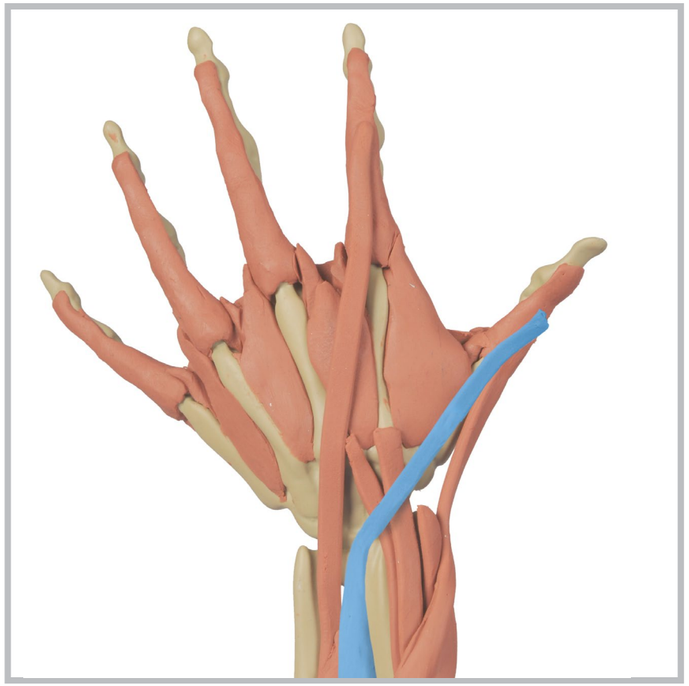

47

An oblique groove in the eminence of radial tuberosity redirects and channels the tendon diagonally across the wrist to run the length of the metacarpal and digit of the thumb.

Once again, a tendon is redirected by skeletal design to control or direct its function. Contracting this muscle will cause the tendon to pull up on the dorsal thumb and curve its tip toward the radial tuberosity, rather than toward its muscle belly that is half-way up the forearm (not shown in this workbook).

extensor pollicis longus m.

48

The area formed by the convergence of the two separated *extensor pollicis* mm. tendons has an interesting traditional nickname: the "anatomical snuffbox." It is so named for the triangular gap formed between the tendons, which—when covered in fascia and skin— produces a shallow depression. This natural hollow was useful for pouring a pinch of snuff before inhaling.

abductor pollicis longus m.

49

Abductor pollicis longus m. attaches at the dorsal base of the metacarpal of the thumb. The other attachment site is alongside the brevis version of this muscle, the dorsal ulna, radius, and interosseus membrane (not shown in this workbook).

50

In this illustration, unsupported by deeper clay forms, a clay tendon coming from the middle of the dorsal forearm should be 3/16-inch thick to hold its shape.

The belly of this muscle layers over the two previous ones, creating a more superficial layer over both. Its tendon wraps around the radial styloid process to the dorsal base of the metatarsal of the thumb at its boundary, the transition from dorsal to ventral.

abductor pollicis longus m.

51

The two tiers of carpal bones are pulled into and held in a palmar arch by a powerful ligament (to be built in steps 101-104) spanning from the tubercle of the ventral trapezium bone to the hamate and pisiform bones at the base of metacarpal V.

In actual building rather than as shown previously in isolation, this more superficial tendon wraps around the deeper tendons.

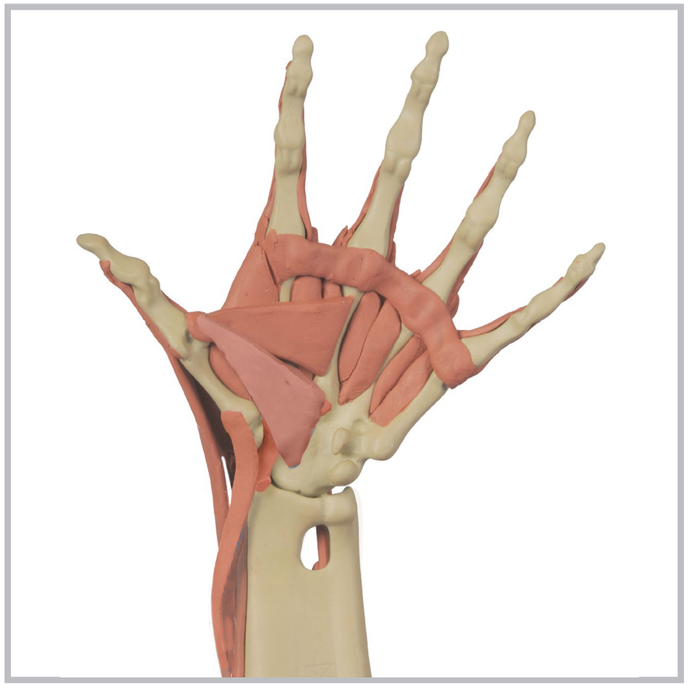

52

extensor carpi ulnaris m.

53

Extensor carpi ulnaris m. attaches to the tuberosity at the dorsal base of the 5th metacarpal bone. At its other end, this extensor muscle shares a common tendon with *extensor carpi radialis* m., which arises from the lateral humeral epicondyle (not shown in this workbook).

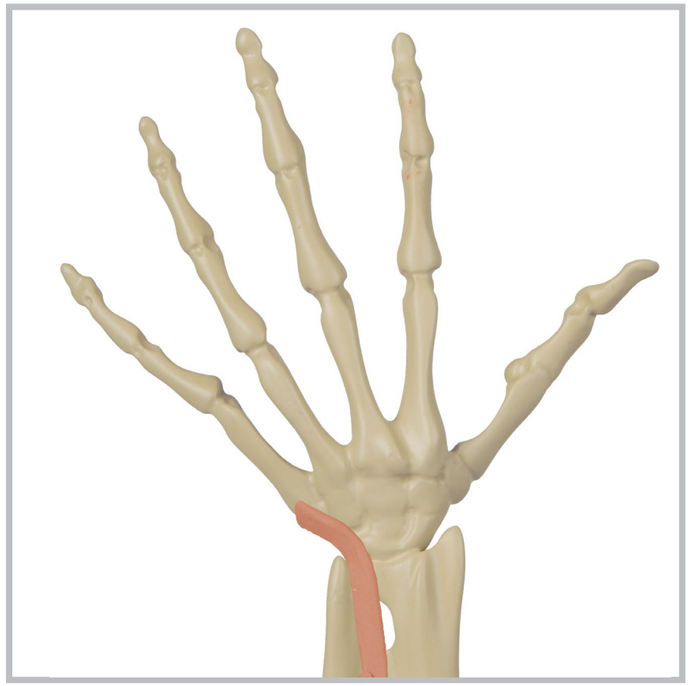

54

Construct the tendon of this muscle as a flat strap of clay similar in shape to the tendons previously built.

The paths of the common tendon described above diverge high in the forearm (not shown in this workbook) well above the radial tuberosity. While the *extensor carpi radialis* m. passes on the thumb side of the tuberosity, the *extensor carpi ulnaris* m. passes through the dorsal sulcus formed by the styloid process of the ulna.

extensor carpi ulnaris m.

55

Grooves alongside the ulnar styloid process are similar to those of the radial styloid process.This styloid also acts as a pulley around which it redirects the tendon outwards to the base of the 5th metatarsal.

It is becoming apparent that the broad sulcus between the groove dorsal to the ulnar styloid and the radial tuberosity is gathering a collection of tendons, a collection that will only grow in number.

56

extensor digitorum m.

57

The attachment sites for *extensor digitorum* m. are the dorsal hoods, which are present on all the digits except the thumb. The proximal end of this muscle attaches at the lateral humeral epicondyle (not shown in this workbook).

58

This is a group of four long clay strap tendons—the puppeteer's strings pulled by the "puppet master's fingers."

These tendons run in parallel together down the forearm in the channel between the radial tuberosity and the ulnar styloid process. They are held together and strapped into that channel by a covering of thick fascia.

Reaching the hand, they leave the channel and fan out before connecting to the dorsal hoods of each of the fingers.

extensor digitorum m.

59

These tendons comprise the most superficial layer of tendons that pass through the sulcus of the dorsal forearm. The eminences of the radial tuberosity and styloid of the ulna act like pulleys as the tendons move.

60

The tendons that are attached to fingers II–V are always described as reaching to the fingertip on each digit. But all they really have to do is join to the hoods, as shown here, in order to attach to each individual phalanx of the fingers.

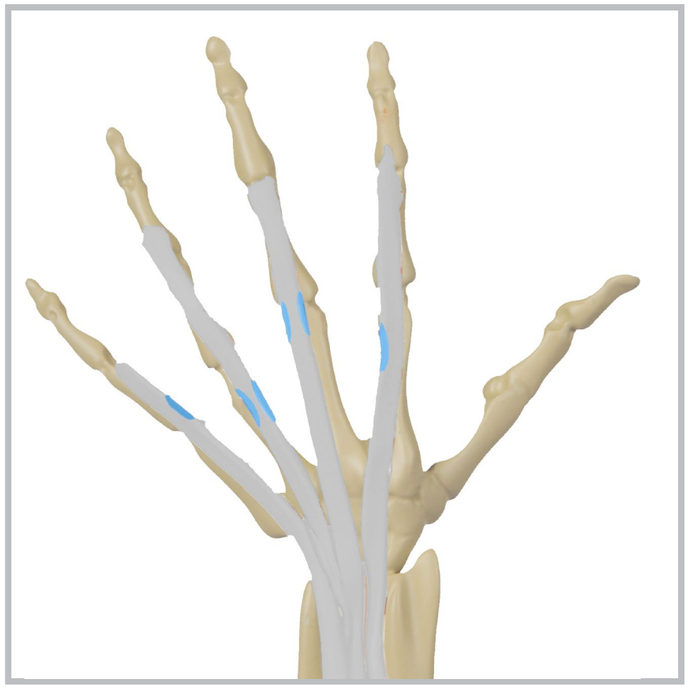

61

These tendons are cross-bridges between the tendons of the *extensor digitorum* mm. The tendons of the *extensor digitorum* mm. are gray in this illustration.

The attachment sites are shown here arising from the edges of these tendons with all the attachment sites shown in blue.

Refer to How to Use this StepByStep™ Workbook on p. 4 for an explanation of why the attachment sites are only shown in blue.

extensor digitorum communis tt.

62

Though the *extensor digitorum* mm. tendons separate after they pass the wrist, they also link with each other through small, flattened clay connectors, which bridge across the tendons' separate branches.

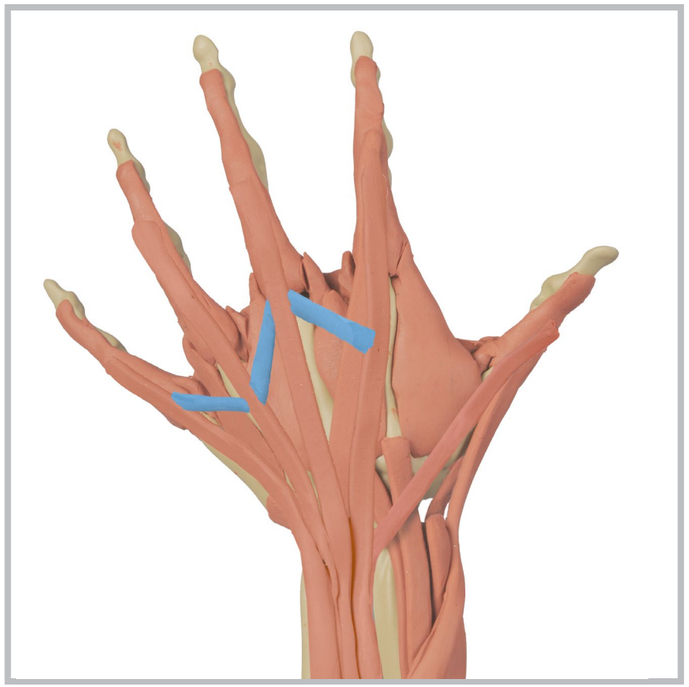

63

Since flexors are responsible for maintaining a firm grip onto a branch—as in the natural environment of the great apes—flexors are less expendable than extensors, which produce reach rather than grasp.

Consequently, extensor tendons tend to be more superficial—exposed—than flexor tendons. The connectors shown here produce a significant degree of redundancy through their communal function.

extensor digitorum communis tt.

64

An enlightening exercise is to try to independently extend, or lift, your ring finger (digit IV). When you do so, your middle and little fingers "jump" as well because they are pulled along through the redunancy created by these tendons.

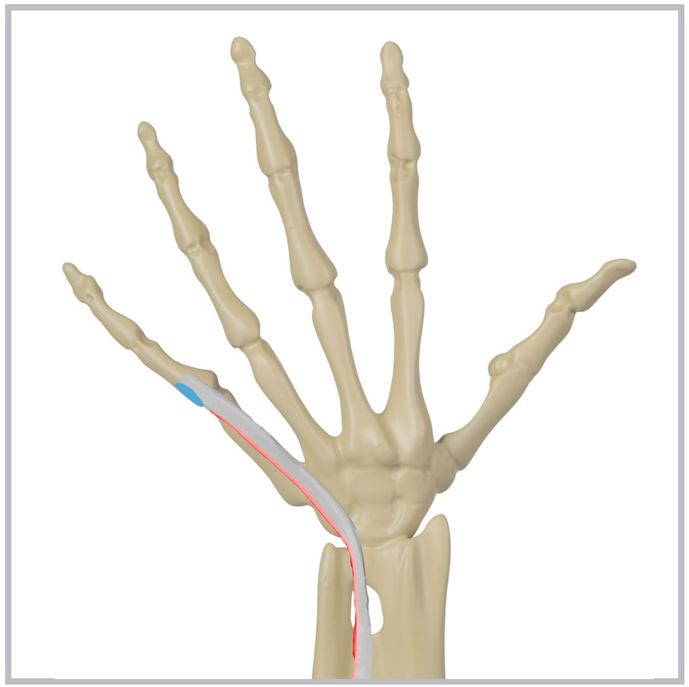

extensor digiti minimi m.

65

The muscle belly and tendon of this muscle are attached along their length to the *extensor digitorum* m. tendon of the 5th digit.

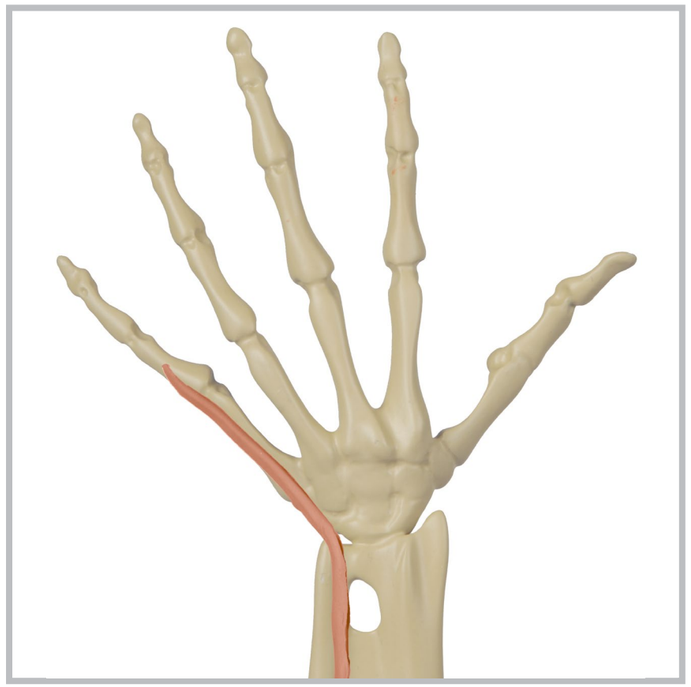

66

Yet another flattened clay strap, this tendon is more delicate in size than the previous tendons.

Note how this tendon attaches to its neighbor along its whole length and also passes through the shared main sulcus.

extensor digiti minimi m.

67

Just as *extensor indicis* m. provides redundancy in straightening the index finger, this muscle provides back-up for extending and straightening the little finger. The result is to widen the distance our hand can span.

68

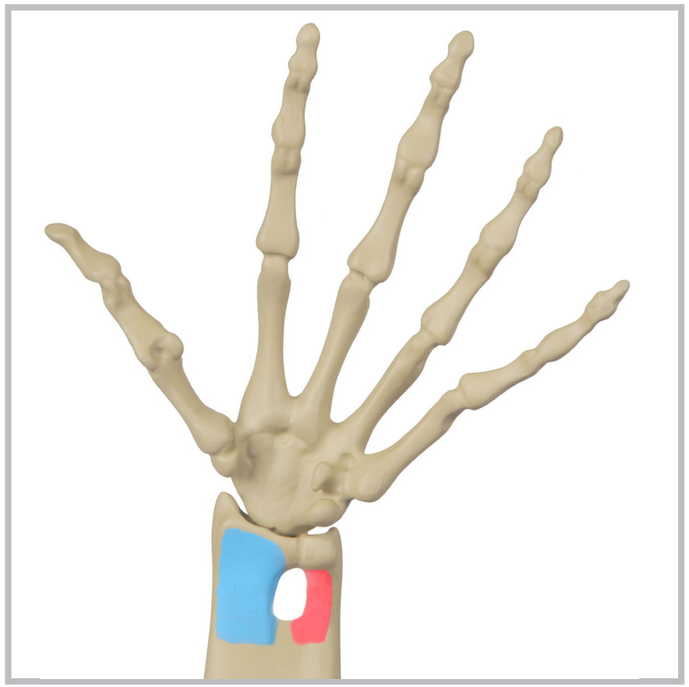

pronator quadratus m.

69

Pronator quadratus m. attaches on the ventral side of the radius and ulna immediately proximal to the radiocarpal joint .

70

This flat clay sheet of muscle— 1/8-inch thick— presents a bed for the tendons of the wrist and hand as they leave the forearm. The wide attachment sites on both radius and ulna provide for a strong muscle despite its relative thinness.

pronator quadratus m.

71

Pronator quadratus m. pulls our radius over our ulna when our hand is freely moving. In some circumstances, such as when the body is hanging by the hands from a bar or branch, it can pronate or supinate the ulna around the radius.

72

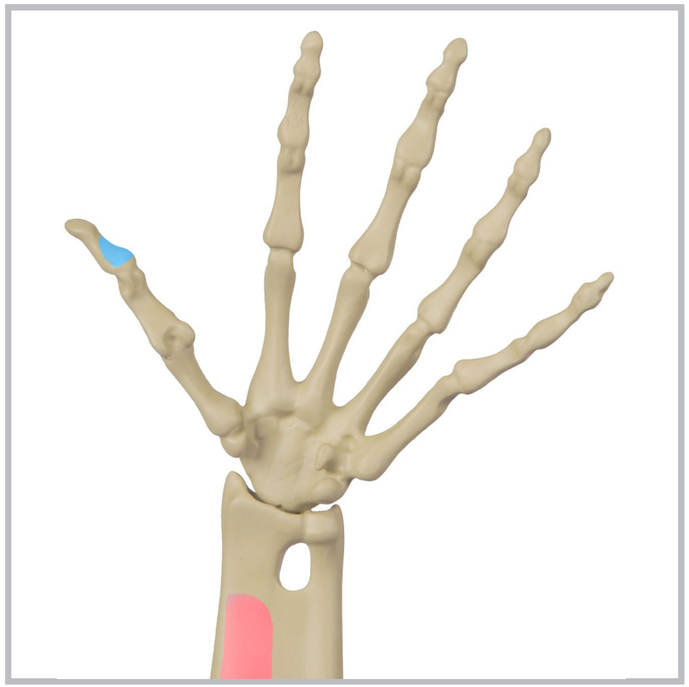

73

The first major muscle of the ventral forearm is the flexor of the thumb. Its proximal attachment is the distal 2/3 of the ventral face of the radius.

Its tendon reaches to the base of the thumb's last phalanx.

flexor pollicis longus m.

74

Moderately rounded, this powerful tendon runs down the radius and across the proximal carpal tier. At the base of the trapezium bone of the distal tier of carpal bones—with which the pollux articulates—a tubercle rises off the palmar surface. Acting like a pulley, this tubercle redirects the tendon with a 45º bend and positions it to follow along the length of the thumb.

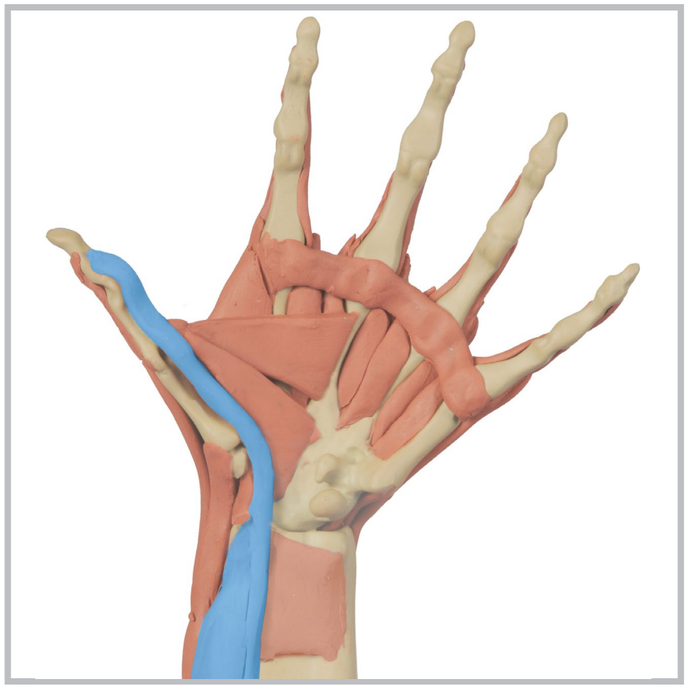

75

Where this tendon runs from the "saddle" joint at the base of the thumb it is straight, but past the metacarpophalangeal joint it is serpentine, following along the surface forms of the palmar side of this digit.

Tendons are under tension between attachment sites, so some anatomical structure must be holding this tendon down against the ventral phalanges of the thumb in order maintain its course. We will build this structure in later steps.

flexor pollicis longus m.

76

Flexor pollicis longus m. is another muscle involved in the repertoire of adduction of the thumb (toward the main ray). In this case, it rolls the pollux over the carpals toward the trapezium, strenging our grasp.

flexor digitorum profundus m.

77

This is the main muscle of the forearm. The proximal attachment site of *flexor digitorum profundus* m. envelopes most of the ulna.The attachment site on the ulna is not shown in this workbook.

At the base of the proximal metacarpal bones, the shared tendon divides into four units that fan out to the bases of the fingers. Each tendon runs along the ventral length of each finger to the base of each finger's distal phalanx.

78

This is easily the most massive muscle of our forearms.The thick single muscle belly separates into four similar tendons after it emerges past the hook of the hamate bone in the distal tier of carpals. The tendons are strong, rounded clay cables, 3/16-inch wide.

flexor digitorum profundus m.

79

The hook of the hamate juts off the ventral hamate carpal bone, where it helps confine the main single tendon into a "carpal tunnel." It also provides the pulley effect for redirecting tendons toward the grooves in the *transverse carpal* l. we have already formed.

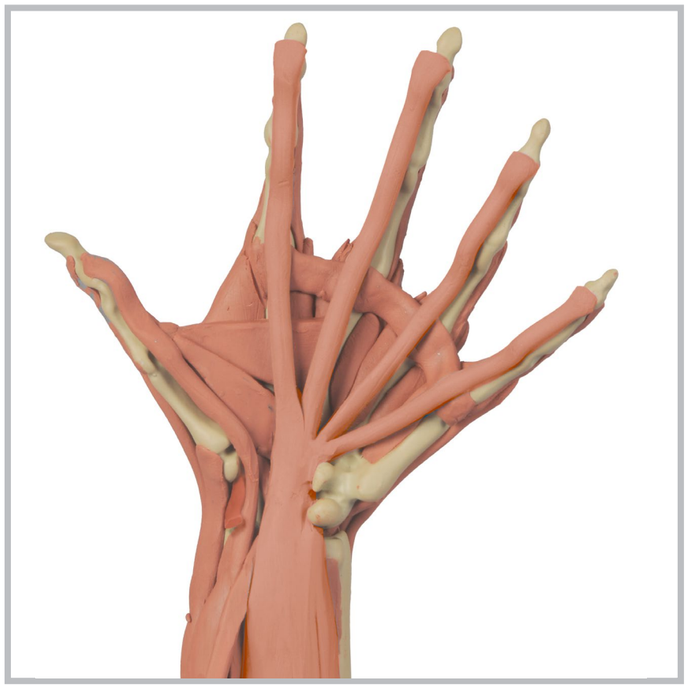

80

The strength we have in our grip was retained as an adaptive form from the arboreal, brachiating arm-dependent movement that is typical of great apes—the group to which human beings belong.

Insights into evolution found in the world of education are vital for understanding all aspects of biological sciences in general and our human nature in specific.

81

All the attachment sites shown are in blue because they are not muscles, and there is no differentiation between proximal and distal in this particular situation. They are small tunnels of connective tissue that attach on ventral edges of all the phalanges—thumb included.

digital tendon sheathes

82

Roll out a 1/16-inch thick strap of clay that is 1/2-inch wide. From this strap, cut sections that will wrap around the long tendons of *flexor digitorum profundus* m. from the medial edge of each finger's 1st and 2nd phalanx to their lateral edges.

After the long round tendons are pressed against the palmar surfaces of the fingers, wrap each of the cut sections around its tendon from edge to edge on the body of each of the phalanges.

83

When the tendons of the ventral fingers are under tension, they still follow the forms of the ventral fingers because of a structural characteristic that redirects their flexion segment by segment. By holding these tendons against the bones, a biomechanical advantage is gained.

In effect, each phalangeal condyle becomes a pulley. Without these pulleys and their ability to redirect the pull of the tendons along the length of the fingers, the tendons would "bowstring" toward the hook of the hamate. As a result, we would lose our ability to flex our fingers and maintain the concavity of our grip at the same time.

digital tendon sheathes

84

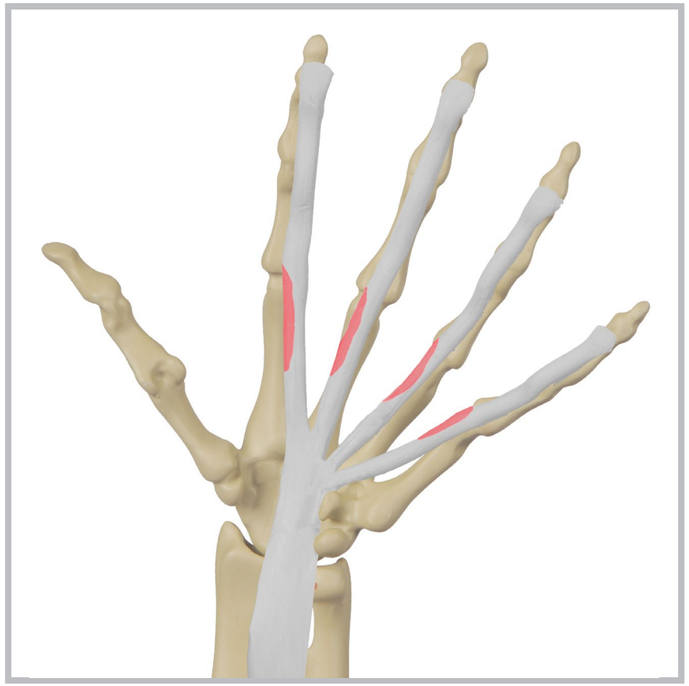

85

Each muscle connects the ventrolateral sides of the tendons of *flexor digitorum profundus* m. to the 2nd digits of the extensor tendons, attaching along the dorsal hoods of the fingers.

The attachment sites of *lumbricales* mm. are not on the skeleton, but rather on the tendons, shown here in gray.

lumbricales mm.

86

Each of these muscles is a small clay tube tapering toward both ends. This illustration depicts them hovering around the fingers, wrapping from ventral to dorsal on the thumb side of each finger.

87

Lumbricales mm. are among the most interesting muscles in the body. By connecting the ventral tendons to the dorsal tendons, they can empower flexion of the metacarpophalangeal joint as well as simultaneously produce a similar power in extension in the intermediate phalanx.

The effect is to enrich the repertoire of motions that the fingers and hand can perform. You can easily flex your proximal knuckles while also extending the fingers straight, or you can maintain extension of the metacarpophalangeal segment while also tightly flexing the next two segments onto each other.

lumbricales mm.

88

The term *lumbricale* means earthworm in Latin, reflecting what early anatomists must have seen in the resemblance of these four small muscles to worms.

89

The belly of this muscle is an expansive sheet that—unlike the analogy of the puppet strings described earlier—is anchored by multiple proximal attachments on the humerus, the ulna, and a diagonal ridge running 2/3 of the length of the proximal radius. These proximal attachment sites are not shown in this workbook.

The tendons of *flexor digitorum profundus* m. terminate on the last phalanx, but *flexor superficialis* m. tendons split into two distal attachments. These are the medial and lateral bases of the intermediate phalanges.

flexor digitorum superficialis m.

90

Make clay straps that are 1/16-inch thick and 1/4-inch wide for these tendons, which split from the sheet of muscle after it passes through the carpal tunnel.

As each flattened tendon runs along its finger it encases the deeper *flexor digitorum* m. tendon until the point at which it splits to reach its distal attachment sites.

91

The tendons of *flexor digitorum superficialis* m. encase their deeper collaborators—strengthening them but not adhereing to them—but they need to find a bony attachment to enhance the versatility as well as power of the human grip.

The superficial tendons accomplish this by dividing evenly into two tips—resembling a swallow's tail—with each tip attaching to the sides and bases of the intermediate digit.

Since the two layers of tendon are not attached to one another, either or both the deep and superficial muscle bellies can flex in a wide range of subtle ways. This is a feature characteristic of other mammals as well.

flexor digitorum superficialis m.

92

93

The distal attachments—the proximal palmar heads of metacarpals II and III—and their stubs of tendon were built in steps 17-20. Those stubs will now be continued into the forearm.

The proximal attachments of *flexor carpi radialis* m. (not shown in this workbook) are located at the medial humeral epicondyle.

flexor carpi radialis m. t.

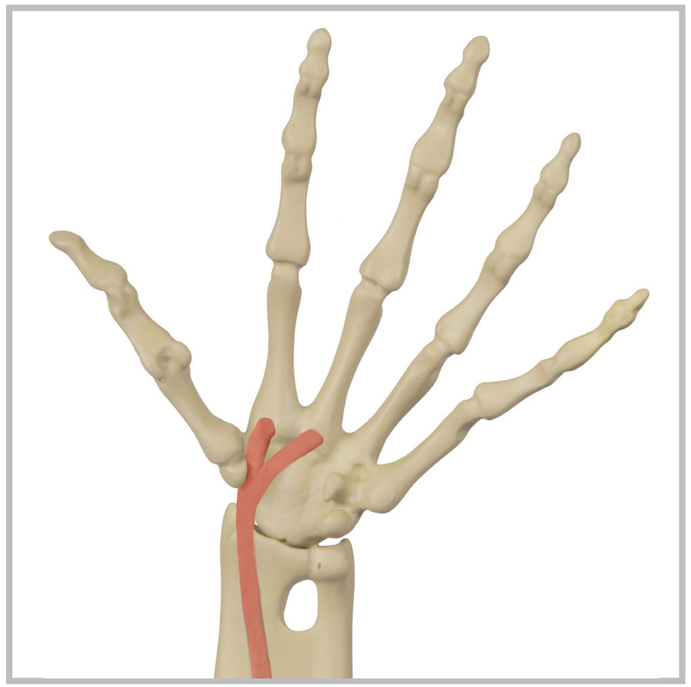

94

Two flattened clay straps join proximally into a single rounded clay tendon that ascends at the wrist.

95

Note how this tendon works its way—from elbow to hand—along the surface of the forearm to the deep wrist, spiralling around the tendons of the *digitorum* mm. series of flexor muscles. Along with the *extensor carpi radialis* m., and *abductor* mm. of the thumb, this muscle produces radial deviation of the hand, movement that rocks it toward the radius.

The surface of the muscle bellies of the flexors of the fingers lie diagonally along the forearm, completing yet another "puppet string" to enlarge the range of motion of the fingers by enabling versatility of the hand.

flexor carpi radialis m. t.

96

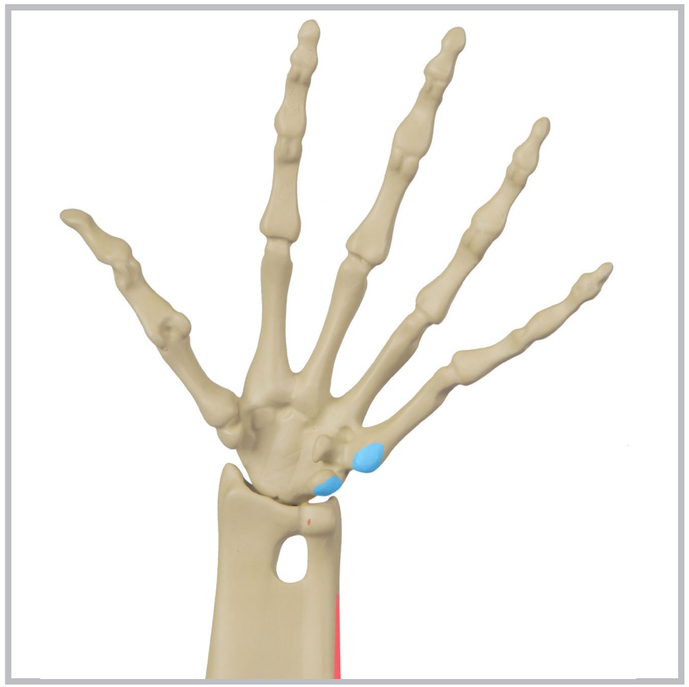

flexor carpi ulnaris m.

97

Flexor carpi ulnaris m. is a companion muscle to *flexor carpi radialis* m. It attaches to the ulnar sides of both the pisiform bone and neighboring metacarpal tubercle.

At the proximal end, it attaches along most of the length of the ulna as well as to the common tendon of both flexors of the wrist at the medial humeral condyle.

98

This clay muscle is roughly triangular in cross section but flattened near the wrist. It does not cross the forearm diagonally but passes straight down the ulna.

flexor carpi ulnaris m.

99

Since both attachment sites of *flexor carpi ulnaris* m. are at the base of the 5th metacarpal bone, this muscle can flex the wrist on the radius toward the ulnar side, a movement sometimes referred to as ulnar deviation.

100

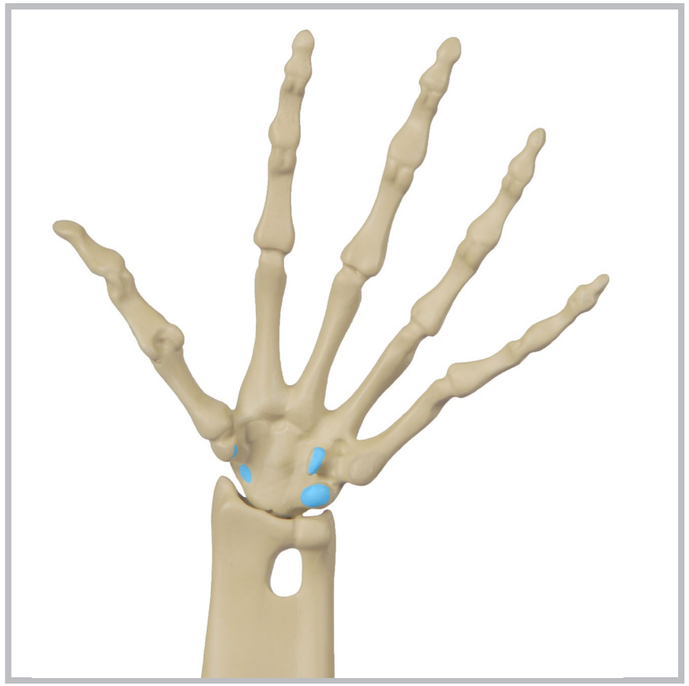

transverse carpal l.

101

Note that the attachment site for the *transverse carpal* l. on the trapezium is not at its tip or crest, but rather on the lateral surface of its side wall. Its other attachment site is shared by the hook of the hamate and the pisiform bone.

102

In this illustration, the thin, flattened clay ligament strap is shown in a color similar to the rest of the skeleton. When added over the clay flexor tendons at the wrist, build it in the same terra cotta color as shown in step 104.

The processes of both the hamate and trapezium are hook-like shapes. These hooks and the lever of the pisiform bone are drawn toward one another by the tension of the ligament so that the three tiers of carpals and metacarpals form an arch.

transverse carpal l.

103

The "carpal tunnel" is formed from the inside of the palmar arch, the bony hooks of the arch, and the transverse carpal ligament. The tendons of the deep flexors of the thumb and fingers and of the superficial flexors of the fingers pass freely under the bridging ligaments of the carpal tunnel.

They then fan out to their digital terminations. Passage through this skeletal "raceway" of bone and ligament contains and then redirects the function of the tendons built so far, with the exception of *flexor carpi radialis* m. The bridge is made of two strong layers of ligaments—one deep and one superficial (yet to be built).

104

No matter how the hand is flexed, extended, or abducted from the main ray from side to side on the radius, the digits all flex toward a common point at the center of the wrist. This common point is produced by the deep layer of the *transverse carpal* l.

flexor retinaculum l.

105

This is the second and more superficial layer of the *transverse carpal* l. The attachments for both layers share nearly the same sites.

106

Flexor retinaculum is formed from a thin sheet of clay. As with the previous ligament, it is shown here in a buff color.

flexor retinaculum l.

107

The thenar—or thumb—side of this layer passes to the summit of the trapezium over the tendon of *flexor carpi radialis* m., capturing it in its own tunnel.

Taken together, these layers retain and channel the tendons of the carpal tunnel, which is composed of *flexors digitorum* mm., *flexor pollicis longus* m., and *flexor carpi radialis* m. at the wrist.

108

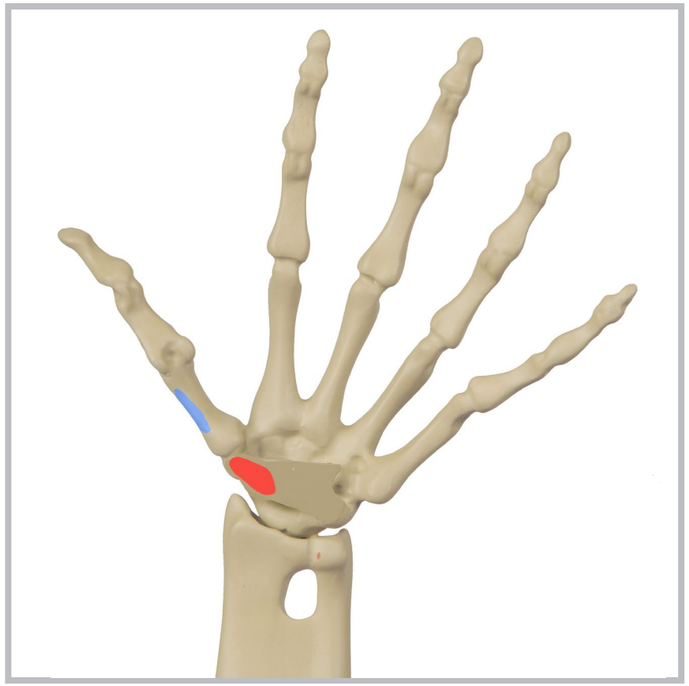

opponens pollicis m.

109

The *transverse carpal* ll. adds surface to the skeletal sites that support muscles arising from the carpal tunnel. Short muscles at the thumb side of the hand will layer over one another to begin formation of the thenar eminence of the palm.

The proximal attachment of this muscle is at the hook-like tubercle of the trapezium. It then spreads beyond it onto the radial side of the *transverse carpal* l. The distal attachment of *opponens pollicis* m. is along the dorsolateral length of the 1st metacarpal.

110

This muscle is a flattened clay band that attaches from the trapezium and its neighboring *transverse carpal* l. and then rolls a bit over it to its lateral crest.

opponens pollicis m.

111

Opponens pollicis m. is just the foundation of the thenar (related to the thumb) eminence.

Humans famously possess uniquely opposable thumbs. What that means is that the tip of the thumb can be made to cross over the palm to its ulnar side, “opposing” it. By bringing the flexed thumb and the tips of any other finger together, this can be even more uniquely termed a “precision grip.”

112

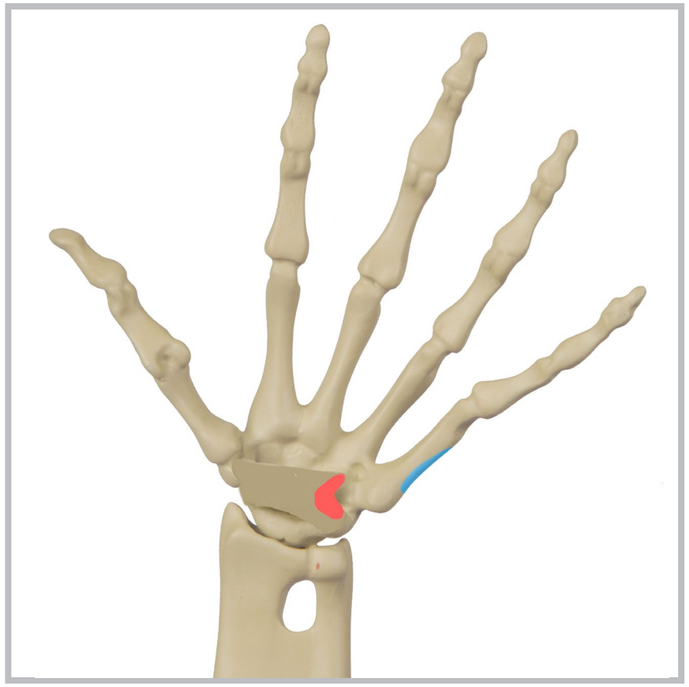

113

The second eminence of muscles on the opposite side of the hand is called the hypothenar eminence. When we stand in the Standard Anatomical Position, with palms forward, the hypothenar eminence is “below” the thenar eminence.

Opponens digiti minimi arises from the levers of the hook of the hamate and of the pisiform bone to attach to the crest along the medial length of the 5th metacarpal.

opponens digiti minimi m.

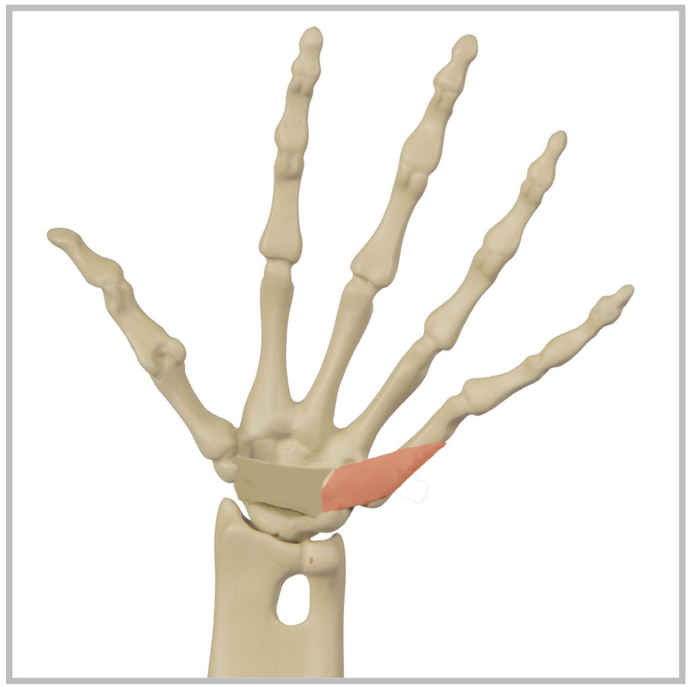

114

This deepest layer of the hypothenar series is a flattened clay band or strap.

115

Together, the *opponens pollicis* m. and this *opponens digit minimi* m. can be recruited at the same time. In this role, they work together to pull both the thumb and little finger toward one another. The effect is to cup the entire hand, as in a handshake or grip, also seen as the arch characteristic of our primate grasping hand.

opponens digiti minimi m.

116

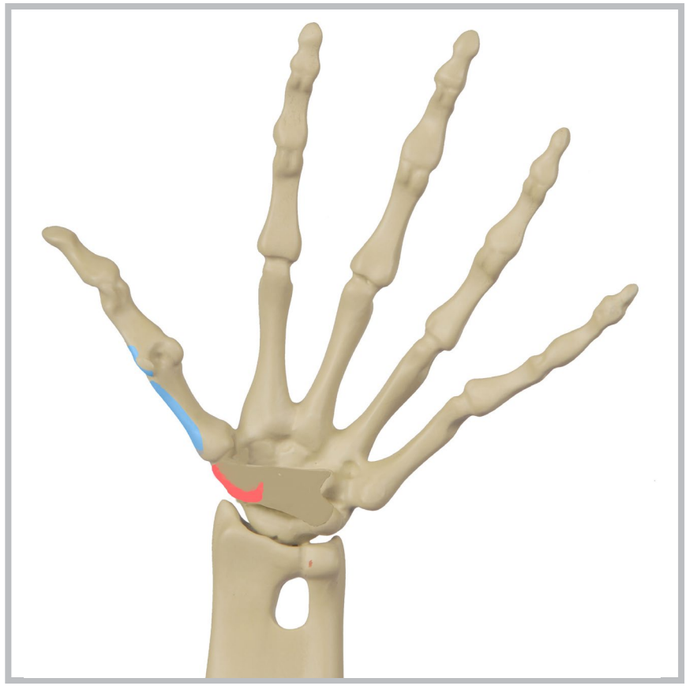

117

The distal tendon of *abductor pollicis brevis* m. overlaps the *opponens pollicis* m.'s attachment on the the 1st metacarpal. Together, the two distal attachments along the metacarpal and proximal phalanx separate ventral from dorsal surfaces of the thumb side of the hand.

abductor pollicis brevis m.

118

Form this and all the following thenar and hypothenar muscles as flattened, boat-shaped straps of clay.

119

An antagonist of the *opponens* m., the *abductor pollicis brevis*. m. pulls the thumb back and away from the center of the palm.

The outline of our palmar hands begins to take shape with *abductor pollicis brevis* m. in place. Remember that the *abductor pollicis longus* m. (steps 49-52) wraps around the styloid process of the radius to reach its attachment at the base of the metacarpal of the thumb.

The progression of abductors along the edge of the thumb's metacarpal and proximal phalanx produces strength.

abductor pollicis brevis m.

120

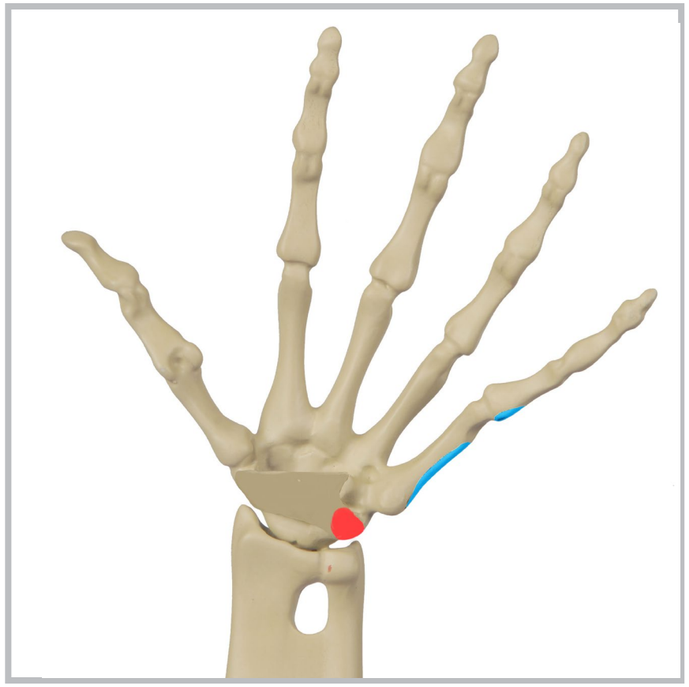

abductor digiti minimi m.

121

Just as in the *abductor pollicis brevis* m., *abductor digiti minimi* m. attaches to the edge of the 5th metacarpal crest on the little finger and on the proximal end to the pisiform bone, with the attachment crossing onto the *flexor retinaculum* ligament.

122

This muscle is formed in the shape of a flattened clay boat. Be certain to attach one edge firmly along the length of the metacarpal crest of the little finger.

abductor digiti minimi m.

123

When you spread out your fingers, notice that both your thumb and little finger move more than the others. This mobility is the basis of our opposable ability and must be antagonized by abduction, in order to draw one or both apart.

124

flexor pollicis brevis m.

125

Flexor pollicis brevis m. is the third muscle of the thenar eminence. Its base shares both the carpal bones and the *transverse carpal* l. The distal attachments, however, are the lateral base of the first phalanx of the thumb and its associated sesamoid bone.

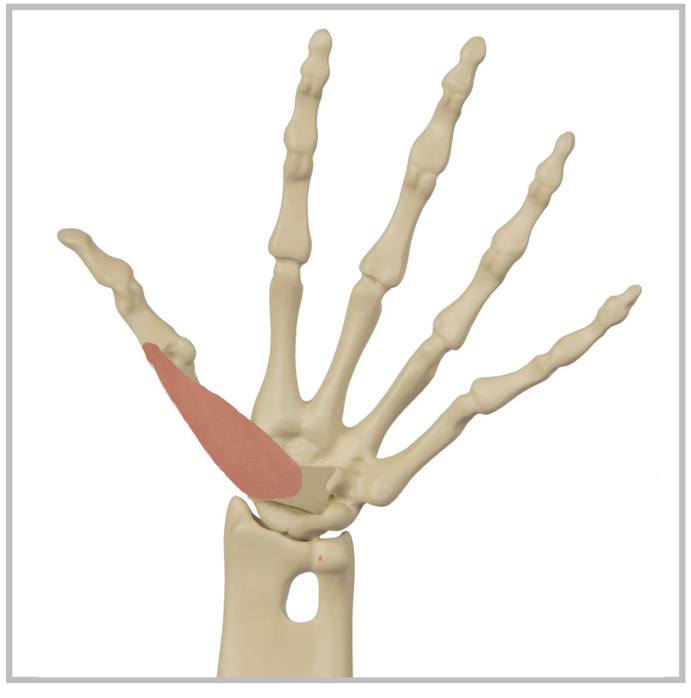

126

This flattened boat-shaped muscle belly overlays the proximal attachment of the *opponens* muscle. At the thumb, the tendon attaching to the pollux encases the lateral sesamoid bone.

flexor pollicis brevis m.

127

Flexor pollicis brevis m. has bypassed the metacarpal bone altogether in order for the thumb to be able to flex independently.

This term explains why the *"longus"* in *flexor pollicis longus* m. is necessary as a qualifier in its nomenclature. It differentiates this muscle from the more general *flexor pollicis* mm.

128

Sesamoid bones—and sometimes cartilage—grow in the tendons t o reinforce them, but also add to mechanical advantage by increasing the angle of force for the tendon.

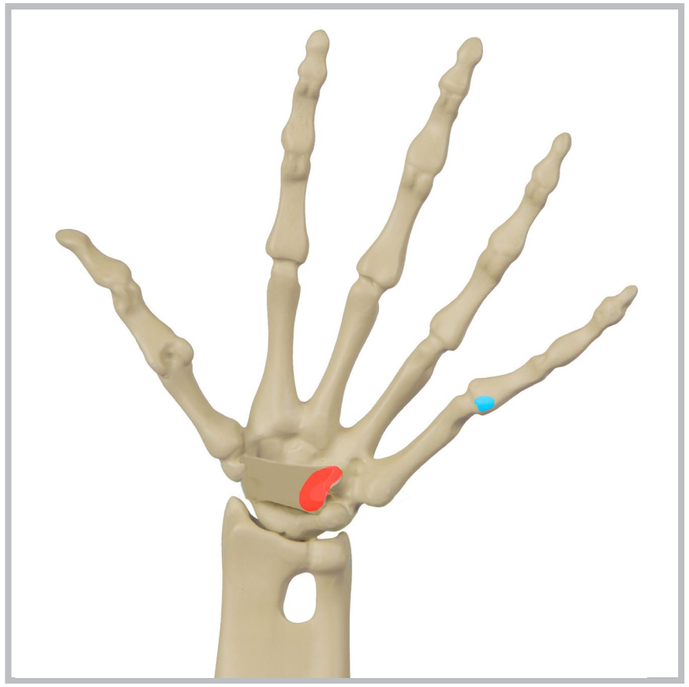

flexor digiti minimi brevis m.

129

This muscle mirrors the attachments of the previous muscle.

130

Like the other clay muscles in this series of hypothenar muscles, this boat form is also flattened. As in the thenar eminence, *flexor digiti minimi brevis* m. completely overlaps the *opponens digiti minimi* m.

flexor digiti minimi brevis m.

131

This completes the hypothenar eminence, the companion to the thenar eminence of the palm.

132

The presence of sesamoids at the 5th metacarpophalangeal joint usually occurs in the hands of those who consistently work with their hands, reflecting how activity can shape body structures.

palmar aponeurosis

133

An aponseurosis is a flattened sheet of fascia, a connective tissue. The *palmaris aponeurosis* arises from fascia encasing the muscles that we have built in the area of the wrist.

Its distal attachments are at the medial and lateral bases of the proximal phalanx of each finger and of the thumb and along the transverse metacarpal ligament (shown here as built at steps 1-4 of this workbook).

134

The *palmar aponeurosis* resembles a glove in which the fingers of the glove have been cut off. Make this structure with a thin, flattened sheet of clay.

The widest side of this triangular sheet of fascia is fastened around the bases of the fingers.

palmar aponeurosis

135

The *palmar aponeurosis* is ventral fascia that is a tough sheet covering and protecting the muscles and tendons of the ventral hand. The fibrous fat and skin of the palm are attached to this fascia.

136

The strongest connections of skin to the palmar fascia are several arcs—these create creases that vary from individual to individual. The thick palm folds easily along these creases in order to maintain a “hollow” that is ready for grasping.

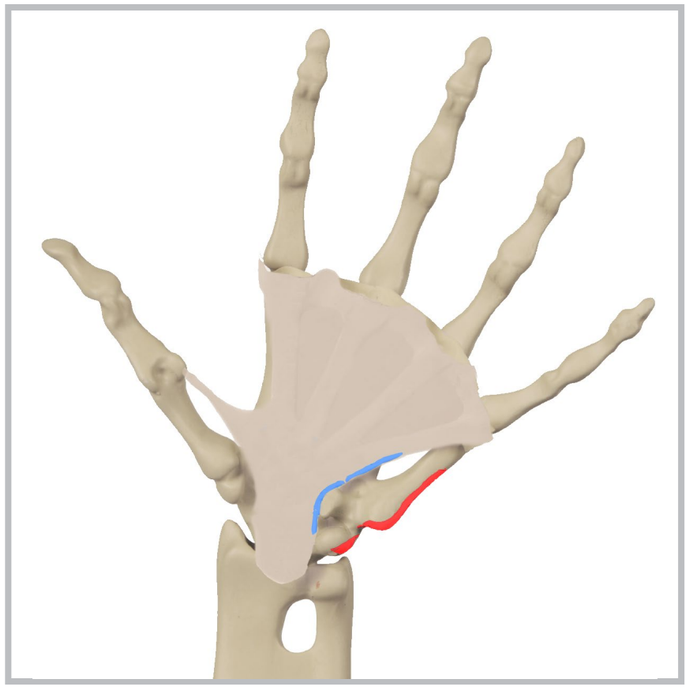

palmaris brevis m.

137

Palmaris muscles are the most superficial of the muscles in the forearm and hand. *Palmaris brevis* m. lies on the surface of the hypothenar eminence, crossing at 90º to the direction of the muscle fibers. This muscle attaches at the ulnar edge of the 5th metacarpal bone and wraps over the eminence to attach along the ulnar edge of the tough sheet of the *palmar aponeurosis*.

138

Actually a group of two separate muscles, *palmaris brevis* m. is formed as two thin sheets of clay that wrap around the hypothenar group of muscles.

palmaris brevis m.

139

Immediately beneath and attached to the skin of the palm, when either or both of these contract, *palmaris brevis* m. puckers the skin at the heel of the hand when either or both of these contract.

140

palmaris longus m.

141

Palmaris longus m. arises proximally from the common tendon at the medial humeral epicondyle (not shown in this workbook). Its fan-shaped distal attachment is on the palmar fascia.

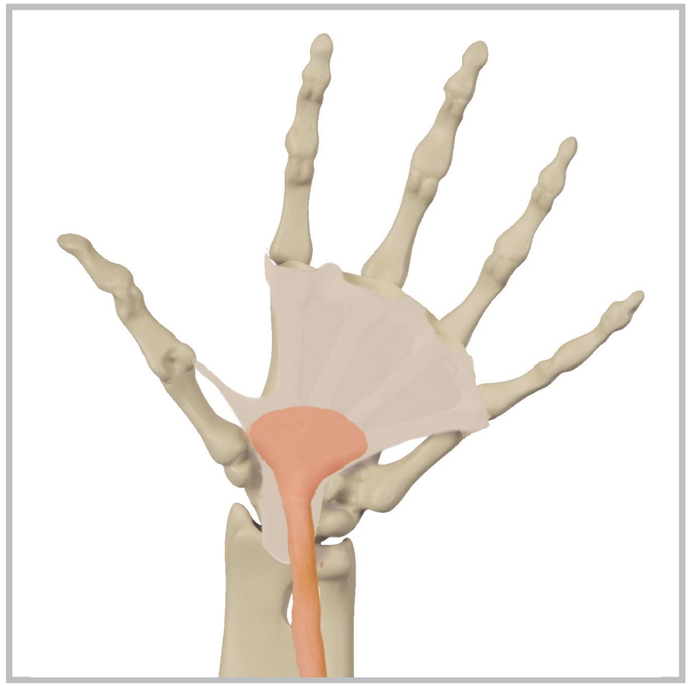

142

The rounded clay tendon fans out and flattens as it attaches at the palmar fascia.

palmaris longus m.

143

The base of the triangular sheet of palmaris fascia is fastened around the bases of the fingers, so that when *palmaris longus* m. contracts, the tendon pulls it toward the elbow and the peak of the triangle is pulled taut. Along with the *palmaris brevis* m., pulling on the aponeurosis from two perpendicular directions stiffens the hand's anatomy powerfully, and therefore contributes to the strength of its grip.

144

According to most sources, about fourteen percent of the population are born without this muscle.

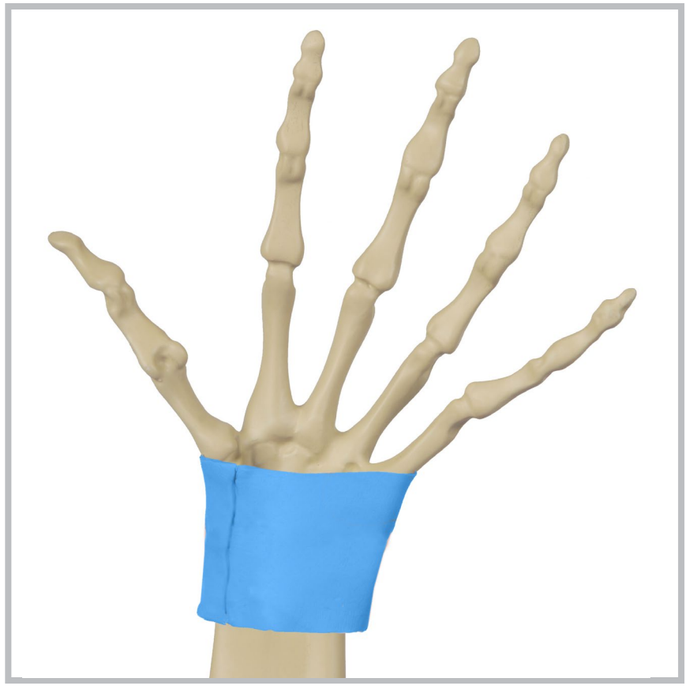

antebrachial retinacular fascia (ventral)

145

Antebrachium is Latin for forearm. This zone of fascia attaches to the surfaces of all the musculature built under it. Therefore, the blue area shown here shows a continual zone of attachment.

This is the ventral view.

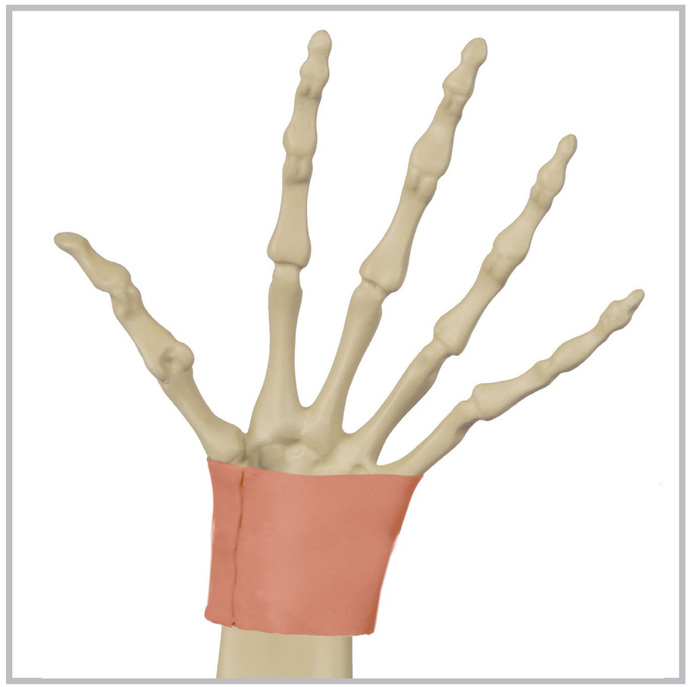

146

Form a wide, flattened clay band large enough to wrap around the wrist. This band helps the two layers of the *flexor retinaculum* built in earlier steps to hold the tendons in place along their paths.

antebrachial retinacular fascia (ventral)

147

Fascia covers all our musculature. It is usually thickest at the joints, both to reinforce them and also to strap them down so that the tendons crossing the articulations stay in their raceways.

Often shown as a strap-like band, only one-third the width shown here, the *antebrachial retinacular fascia* actually represents the strongest zone of the packaging of the joint.

148

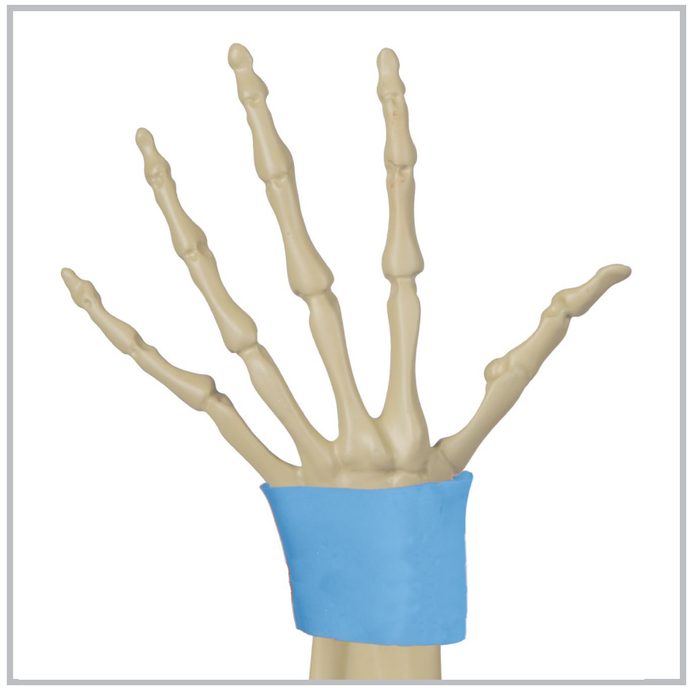

antebrachial retinacular fascia (dorsal)

149

This is the dorsal view of the band we built previously.

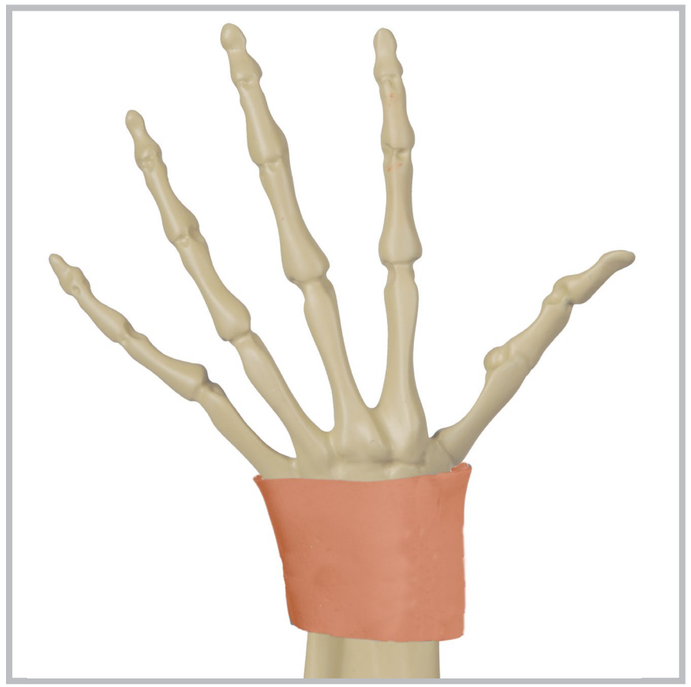

150

antebrachial retinacular fascia (dorsal)

151

The tendons along the back of the hand—the dorsal side—are immediately beneath the skin, unlike those on the other side, where they are deep within a strong glove of palmar fascia.

This fascia might be said to create a "tunnel" for each tendon or set of tendons, holding them in place so that their muscles function predictably.

152

It is typical in vertebrate appendages that the ventral and dorsal compartments of muscle and bone are considerably different. Bringing two ventral surfaces toward one another is *flexion* and in the opposite— dorsal surface to dorsal surface— the movement is referred to as *extension*.

In each case, the work of the ventral flexors is usually more necessary for vertebrates than that of their antagonists, the extensors. Consequently, in the hand the extensor tendons are less well-protected than those of the flexors.

SuperManiken or MidiManiken™ Model Model

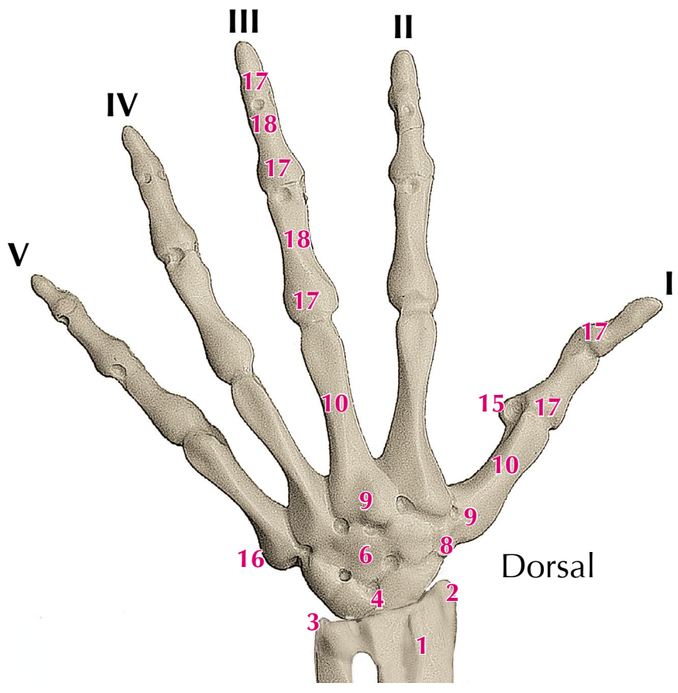

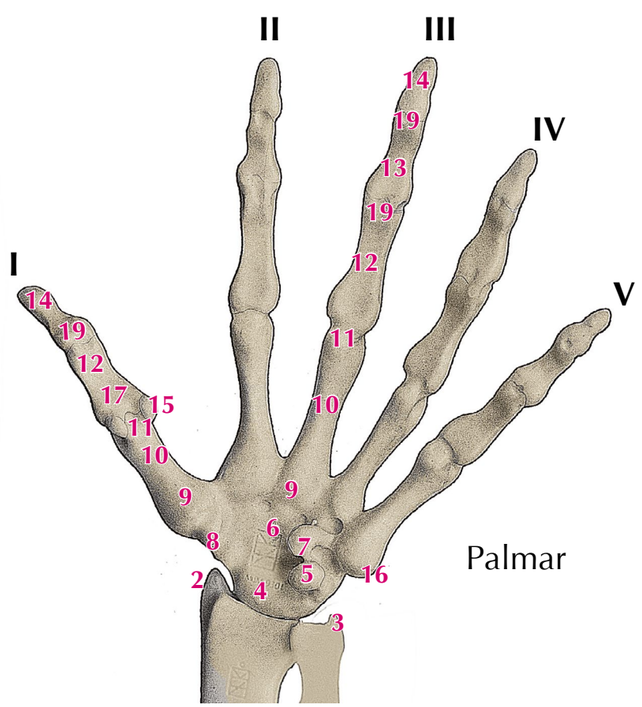

1 radial tubercle
2 radial styloid process
3 ulnar styloid process
4 proximal tier of carpals
5 pisiform
6 distal tier of carpals
7 hamate
8 trapezium
9 metacarpal base
10 metacarpal shaft
11 metacarpal condyle (head)
12 proximal phalanx
13 intermediate phalanx
14 distal phalanx
15 medial sesamoid
16 tubercle of 5th metacarpal
17 phalangeal base
18 phalangeal shaft
19 phalangeal condyles

Human Skeleton

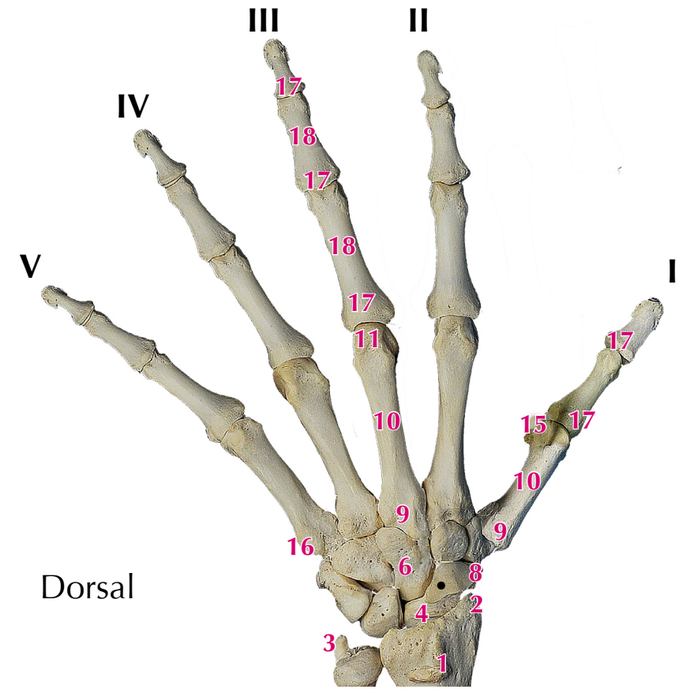

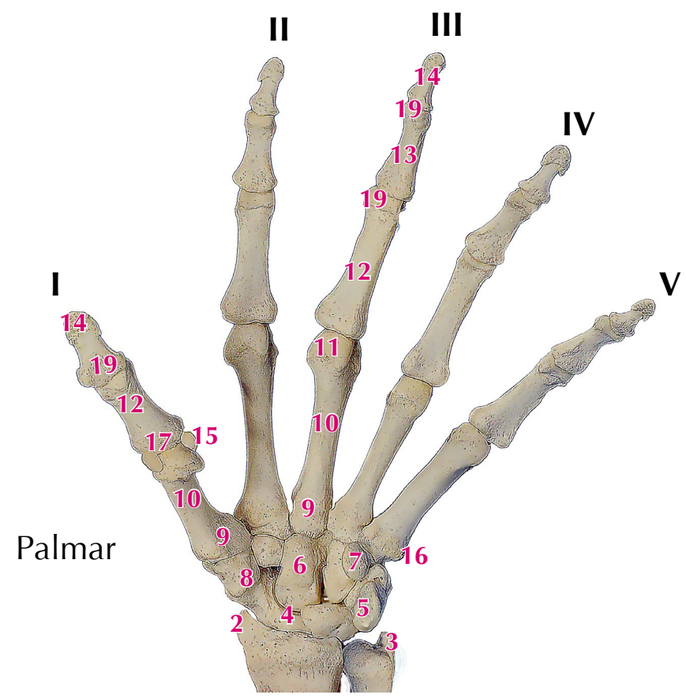

1 radial tubercle
2 radial styloid process
3 ulnar styloid process
4 proximal tier of carpals
5 pisiform
6 distal tier of carpals
7 hamate
8 trapezium
9 metacarpal base
10 metacarpal shaft
11 metacarpal condyle (head)
12 proximal phalanx
13 intermediate phalanx
14 distal phalanx
15 medial sesamoid
16 tubercle of 5th metacarpal
17 phalangeal base
18 phalangeal shaft
19 phalangeal condyles

Essential Terms

abduct. To pull away from the median or center.

adduct. To pull toward the median or center.

aponeurosis. A sheet of tendon or heavy fascia.

axial. Toward the line marked by the vertebral segments and thoracic elements, as they are aligned from the head to the tip of the tail.

caudal. The coccyx or tail, or in the direction of the tail.

condyle. A rounded protuberance at the end of a long bone, forming one part of an articulation between bones.

cranial. Toward or in the direction of the top of the head (from the Latin word *cranium*, for skull.

distal. Usually used in reference to one anatomical point that is relatively farther from another point from the median of the body. Opposite of prox imal.

dorsal. The back or in the direction of the back.

epicondyle. A tubercle immediately proximal from a condyle.

extensor. Any muscle that brings two dorsal surfaces toward each other is considered an extensor. The opposite of flexor.

extrinsic. As used in this publication, referring to a muscle or muscles that attach two different and adjacent skeletal subsystems, such as those connecting the axial to the pelvic subsystem.

fascia. Envelopes and connective tissues of collagen fibers in a wide range of thickness that encases anatomical forms.

flexor. Any muscle that brings two ventral surfaces toward each other is considered a flexor. The opposite of extensor.

intrinsic. As used in this publication, referring to a muscle or muscles with attachment sites that are within a single skeletal subsystem, such as one connecting one pectoral bone to another.

lateral. On or toward the side, away from the median.

ligament. Connective tissue of strong collagen fibers and lacking "elastin" fibers, which are laid in a parallel linear pattern to connect bones in an articulation (joint). Their tensile strength restricts undesirable motion in a joint.

medial. On or towards the midline center of the body.

metacarpals. Long bones of the palm of the hand between the carpal (wrist) bones and against which the phalanges, or digits, articulate.

phalanges. The collective name for the bones that comprise a digit, either finger or toe.

phalanx. The singular name for each of the component bones in a digit, either finger or toe.

prone. Lying face down when horizontal, with the dorsal (back) surface facing up.

distal. Usually used as a reference of position, referring to an anatomical point relatively closer than another point to the median of the body.

ray. The metacarpal and its finger or the metatarsal and its toe. The third (middle) finger is the main ray in the hand; the second toe is the main ray in the foot.

retinaculum. A band of fascia wrapping around the tendons that runs along the bones of a joint to hold them in their anatomical grooves, providing predictable functions in an articulation.

Standard Anatomical Position. A position of the body when standing bipedally erect, balanced equally over the feet, and with the arms falling to the sides of the body. This is the conventional position for anatomical reference as to orientation and the relationships of body parts.

supracondylar ridge. A ridge that extends proximally from the condyle of a joint and above it in the Standard Anatomical Position.

sulcus. A groove or furrow in a skeletal form of bone or cartilage.

supine. Lying face up when horizontal, with the ventral belly surface facing up.

proximal. Closest to the median. Opposite of distal.

tendon. Strong band of collagen connective fabric that connects an end of a muscle to its attachment site on a bone. Tendons actually attach to the *periosteum*, a fabric-like covering of the bone.

ventral. Towards or closest to the belly. Opposite of dorsal.

© 2012, 2013 Jon Zahourek

Sequential Table of Contents

Alphabetical Table of Contents

ANATOMY IN CLAY®
Publications
ZAHOUREK SYSTEMS™

THE MIND CANNOT FORGET WHAT THE HANDS HAVE LEARNED™

ZAHOUREK SYSTEMS™
zsi@anatomyinclay.com
2198 West 15th St.
Loveland, CO
80538-3597, USA
[970] 667-9047

JZP•13-001